

Upper Extremity Regional Anesthesia Essentials of Our Current Understanding, 2008

Joseph M. Neal, MD,* J.C. Gerancher, MD,† James R. Hebl, MD,‡ Brian M. Ilfeld, MD, MS,§
Colin J.L. McCartney, MBChB,|| Carlo D. Franco, MD,¶ and Quinn H. Hogan, MD#

Abstract: Brachial plexus blockade is the cornerstone of the peripheral nerve regional anesthesia practice of most anesthesiologists. As part of the American Society of Regional Anesthesia and Pain Medicine's commitment to providing intensive evidence-based education related to regional anesthesia and analgesia, this article is a complete update of our 2002 comprehensive review of upper extremity anesthesia. The text of the review focuses on (1) pertinent anatomy, (2) approaches to the brachial plexus and techniques that optimize block quality, (4) local anesthetic and adjuvant pharmacology, (5) complications, (6) perioperative issues, and (6) challenges for future research.

(*Reg Anesth Pain Med* 2009;34: 134–170)

Upper extremity regional anesthesia has been a mainstay of the anesthesiologist's armamentarium since Hall¹ first reported the use of cocaine to block the brachial plexus in 1884. Recognizing that upper extremity neural blockade represents the most frequent use of peripheral nerve blocks in most anesthesiologists' practice,² in 2001, the American Society of Regional Anesthesia and Pain Medicine (ASRA) undertook a critical review of all available English-language publications pertinent to this topic. The resulting extensive source document was synthesized into a comprehensive review article³ that was published in 2002; both the source and the review documents will be updated approximately every 5 years.

Rather than publishing only new material that has become available since 2002, the original review article has been completely revised so that readers may continue to view the subject matter in its entirety. New topics in this review include ultrasound-guided brachial plexus block, continuous catheter-based analgesia, and a collection of new images* by medical illustrator, Jennifer Gentry (www.gentryvisualization.com). This review summarizes the essential scholarly work available from the source document, which can be viewed at www.asra.com.

From the *Department of Anesthesiology, Virginia Mason Medical Center, Seattle, WA; †Department of Anesthesiology, Wake Forest University, Winston-Salem, NC; ‡Department of Anesthesiology, Mayo Clinic, Rochester, MN; §Department of Anesthesiology, University of California, San Diego, San Diego, CA; ||Department of Anesthesiology, University of Toronto, Toronto, Ontario, Canada; ¶Department of Anesthesiology, Rush University Medical Center, Chicago, IL; and #Department of Anesthesiology, Medical College of Wisconsin, Milwaukee, WI.

Accepted for publication November 14, 2008.

Address correspondence to: Joseph M. Neal, MD, 1100 Ninth Ave (B2-AN), Seattle, WA 98101 (e-mail: anejmn@vmmc.org).

Dr. Ilfeld is supported by NIH grant GM077026 (Bethesda, MD).

The contents of this article are solely the responsibility of the authors and do not necessarily represent the official views of this entity.

James P. Rathmell, MD, served as acting editor-in-chief for this article.

Financial support: None.

Copyright © 2009 by American Society of Regional Anesthesia and Pain Medicine

ISSN: 1098-7339

DOI: 10.1097/AAP.0b013e31819624eb

This review article strives (1) to serve as a review of pertinent anatomy, (2) to compare the effectiveness of brachial plexus approaches and techniques, (3) to present available evidence to guide selection of pharmacological agents, (4) to describe the complications inherent to upper extremity anesthesia, (5) to consider pertinent perioperative issues, and (6) to identify informational gaps and emphasize where we believe further study is warranted.

BRACHIAL PLEXUS ANATOMY

Neural Elements

Performing upper extremity regional anesthesia requires a thorough knowledge of brachial plexus anatomy to facilitate the technical aspects of block placement and to optimize patient-specific block selection. *Gray's Anatomy* describes the brachial plexus as that network of nerves that begin as spinal nerve roots and continue to the terminal branches that supply the upper extremity. The brachial plexus starts as the union of the ventral primary rami of cervical nerves 5 through 8 (C5–C8), including a greater part of the first thoracic nerve (T1). Variable contributions may also come from the fourth cervical (C4) and the second thoracic (T2) nerves.⁴ The ventral rami are the roots of the brachial plexus. The C5 and C6 rami typically unite near the medial border of the middle scalene muscle to form the superior trunk of the plexus; the C7 ramus becomes the middle trunk; and the C8 and T1 rami unite to form the inferior trunk (Fig. 1). The C7 transverse process lacks an anterior tubercle, which facilitates the ultrasonographic identification of the C7 nerve root.⁵ The roots and trunks pass through the interscalene groove, a palpable surface anatomic landmark between the anterior and middle scalene muscles (Figs. 1–3). The 3 trunks undergo primary anatomic separation into anterior (flexor) and posterior (extensor) divisions at the lateral border of the first rib. Divisions undergo yet another level of reorganization into cords, which are defined by their spatial relationship to the second part of the axillary artery. The anterior divisions of the superior and middle trunks form the lateral cord of the plexus, the posterior divisions of all 3 trunks form the posterior cord; and the anterior division of the inferior trunk forms the medial cord. The 3 cords divide and give rise to the terminal branches of the plexus, with each cord possessing 2 major terminal branches and a variable number of minor intermediary branches.⁴ The lateral cord contributes the musculocutaneous nerve and the lateral component of the median nerve. The posterior cord generally supplies the dorsal aspect of the upper extremity via the radial and axillary

*ASRA members may obtain jpeg files of ASRA-copyrighted images free-of-charge from www.asra.com. The illustrations may be used only for noncommercial, nonpublication educational endeavors. Permission to reprint the illustrations in journals, books, or other media must be obtained from ASRA. The images may not be modified.

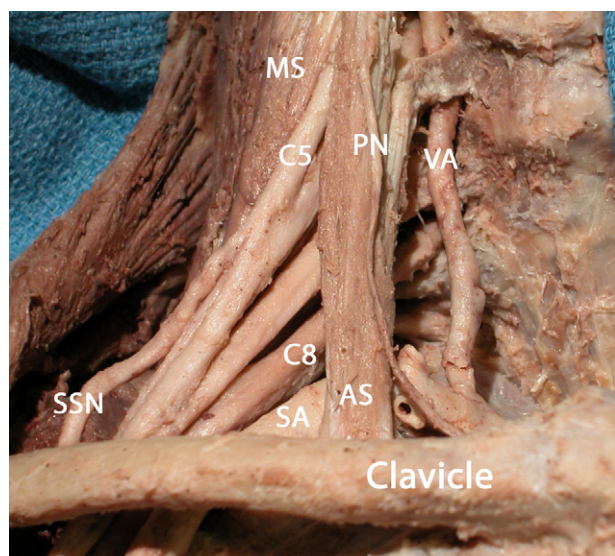


FIGURE 1. Dissection of the right brachial plexus. The vertebral artery (VA) is medial to the anterior scalene muscle (AS) and travels anterior to the plexus before entering the canal formed by the vertebral transverse process. The phrenic nerve (PN) overlies the anterior scalene muscle. The C5 and C6 nerve roots join to form the upper trunk. MS indicates middle scalene muscle; SA, subclavian artery; SSN, suprascapular nerve; C8, C8 nerve root. Dissection and photo courtesy of Carlo D. Franco, MD. Modified with permission from Franco and Clark. *Tech Reg Anesth Pain Manag.* 2008;12:134 (Elsevier).

nerves. The medial cord contributes the ulnar nerve and the medial component of the median nerve. Important intermediary branches of the medial cord include the medial antebrachial cutaneous nerve and the medial cutaneous nerve, which joins with the smaller intercostobrachial nerve (T2) to innervate the skin over the medial aspect of the arm. Figure 4 illustrates an idealized brachial plexus.

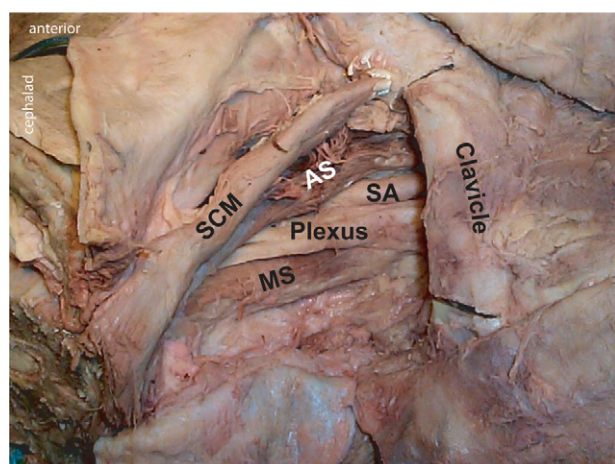


FIGURE 2. Dissection of the right interscalene area. The brachial plexus is contained within connective tissue and traverses between the anterior (AS) and middle (MS) muscles. The plexus is lateral to the subclavian artery (SA). SCM indicates sternocleidomastoid muscle. Photo courtesy of Quinn H. Hogan, MD.

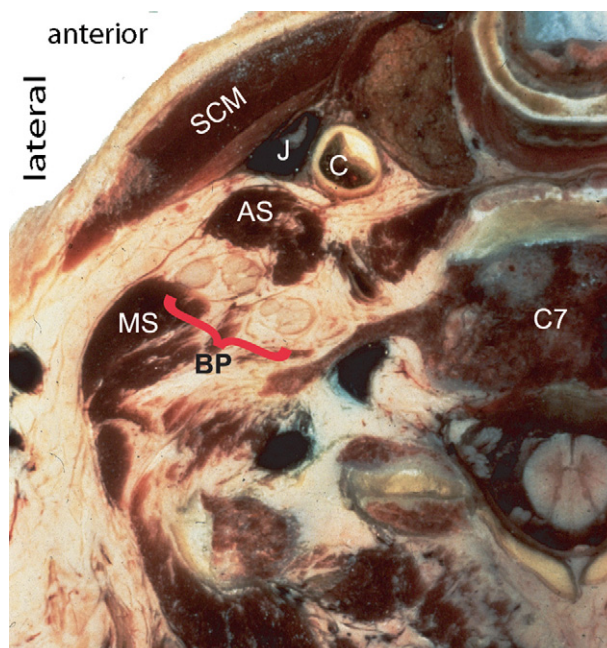


FIGURE 3. Cryomicrotome section of the left neck at the C7 level. The brachial plexus (BP) lies between the anterior (AS) and middle scalene (MS) muscles. Note the closeness of the brachial plexus to the skin and to the vertebral canal and its contents. SCM indicates sternocleidomastoid muscle; J, jugular vein; C, carotid artery. Cryomicrotome courtesy of Quinn H. Hogan, MD.

Despite the aforementioned “classic” schema, 7 major configurations of the brachial plexus have been described, with none having more than a 57% representation; indeed, 61% of individuals exhibit right/left asymmetry.⁶ These normal anatomic variations take on particular importance during ultrasonic examination of the upper extremity neural components, which makes it easier to directly visualize normal variants such as a solitary trunk, a postfixed plexus wherein contribution from T2 leads to a lesser or absent C5 nerve root,⁷ or C5 and C6 nerve roots that penetrate the anterior scalene muscle rather than reside within the interscalene groove.^{8,9} Whether these anatomic variations significantly impact the successful provision of upper extremity regional anesthesia is unknown.

The architecture of the brachial plexus and the structure of peripheral nerves contribute to understanding the pathophysiology of perioperative nerve injury (Fig. 5). Peripheral nerves are constructed of a varying number of fascicles that consist of individual nerve fibers (axons) that are contained within endoneurium. Fascicles are contained within perineurium, while groups of fascicles are contained within epineurium. As the nerve travels away from the spinal cord, the density of the epineurium (stroma and connective tissue) diminishes, but its total volume increases. The amount of neural tissue remains constant. Thus, the ratio of nonneural to neural tissue contained within the epineurium increases from 1:1 in the proximal plexus to 2:1 in the distal plexus, where the cross-sectional area of a peripheral nerve may consist of up to 70% loose connective tissue.¹⁰ The possible clinical significance of this observation is that when a needle unintentionally enters a peripheral nerve, it does not invariably come to rest within a fascicle but may instead lie within connective tissue.

Peripheral nerve anatomy also determines patterns of local anesthetic blockade and clearance. Local anesthetic is first

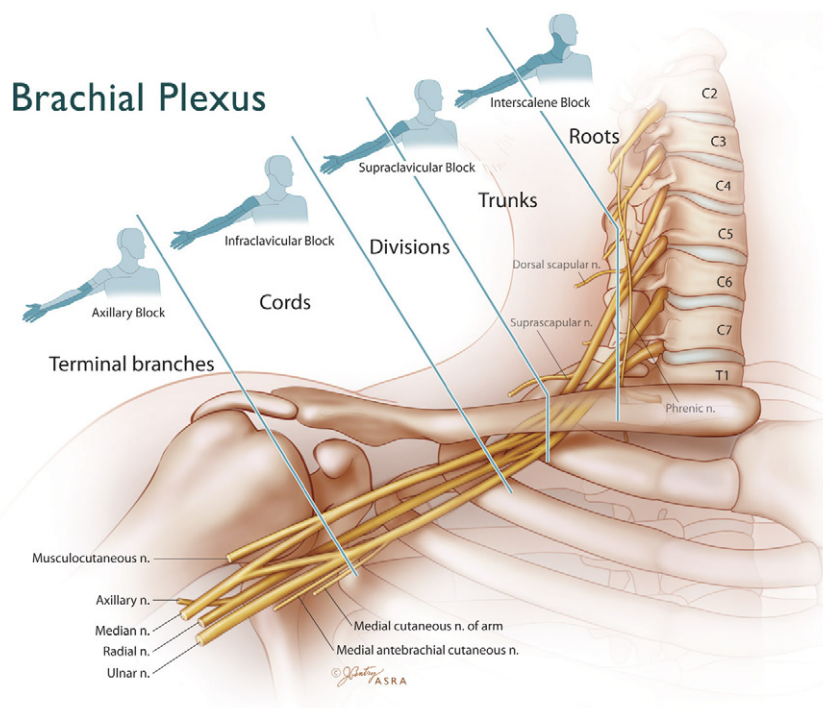


FIGURE 4. Idealized brachial plexus. Various approaches define individual brachial plexus blocks and their expected distribution of cutaneous anesthesia. Illustration by Jennifer Gentry. ©American Society of Regional Anesthesia and Pain Medicine.

absorbed by the mantle fibers on the nerve's periphery, resulting in blockade that manifests itself proximal to distal. Conversely, block resolution follows a distal-to-proximal pattern, suggesting that local anesthetic is preferentially cleared from the core fibers by the core's vascularity (Fig. 5).¹¹ The increased ratio of nonneural to neural tissue as one moves away from the spinal cord may also explain the relatively longer block onset times with distal as opposed to more proximal approaches.¹⁰

Other Pertinent Neuroanatomy

Several nerves that are either significant branches of, or not an actual part of, the brachial plexus are clinically important with regard to upper extremity surgery because they may require separate blockade or indicate needle malposition. The supraclavicular nerves, which are branches of the superficial cervical plexus (C3-C4), provide sensory innervation to the "cape" of the shoulder, from the anterior second rib over the shoulder and down to the top of the scapula. The phrenic nerve (C3-C4, occasionally C5) overlies the anterior scalene muscle, where it can be unintentionally stimulated if the block needle is directed too far anterior during interscalene block (ISB). The C5 anterior rami and the phrenic nerve are separated only by 2 mm; the distance between these 2 structures increases as one moves caudad.¹² Stimulation of the dorsal scapular nerve (C5) causes rhomboid and levator scapulae motor responses and indicates that the block needle is directed too far posterior. The supraclavicular nerve (C5-C6) branches from the upper trunk and sends sensory fibers to the shoulder capsule and the acromioclavicular joint. The intercostobrachial nerve originates from the second intercostal nerve (T2) and, with the medial cutaneous nerve, innervates the upper half of the posterior and medial skin of the arm.

Sensory and Motor Innervation of the Arm

The sensory and motor innervation of the upper extremity is clinically important, determining which cutaneous nerve distributions within a surgical field require conduction blockade, which terminal nerve branches require supplementation for an incomplete block, and determining the existence and distribution of preoperative and postoperative neurological deficit. The cutaneous nerves of the upper extremity are a collection of neural fibers that originate from a variety of spinal cord segments. Assigning cutaneous territory to a specific peripheral nerve is inconsistent, if not impossible (Fig. 6). Indeed, this situation significantly compromises rigorous evaluation of sensory blockade in most research studies. Motor innervation is clinically relevant as a means of matching a peripheral nerve stimulator (PNS)-induced motor response to the major nerve(s) that has been stimulated. For example, superior trunk stimulation results in a deltoid motor response. Musculocutaneous nerve stimulation causes the arm to flex at the elbow. Median nerve stimulation results in forearm pronation, wrist flexion, and thumb opposition. Ulnar nerve motor responses include ulnar deviation of the wrist, little-finger flexion, thumb adduction, and flaring of the fingers. Wrist and finger extensions are the hallmark of radial nerve stimulation.

Assessing the Extent of Brachial Plexus Blockade

Because innervation of the arm comes from different nerves, the extent of blockade is best assessed by evaluating functions unique to each terminal nerve. A method of performing such an assessment is the 4 P's.¹³ The patient is asked to push the arm by extending the forearm at the elbow against resistance (radial nerve), followed by resisting the pull of the forearm at the elbow (musculocutaneous nerve). The median nerve is assessed by the ability to distinguish a pinch at the

Peripheral Nerve Anatomy

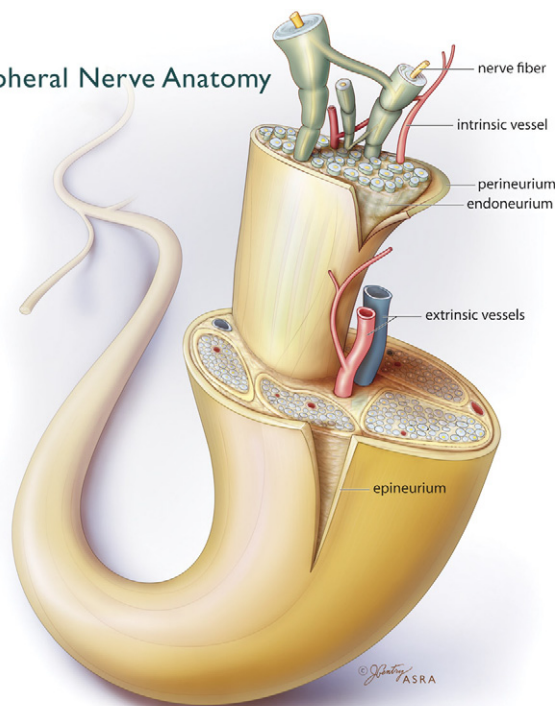


FIGURE 5. Peripheral nerve anatomy. Nerves are a collection of individual axons, which are surrounded by loose endoneurium and freely interdigitate along their course (12-o'clock). Axons receive nutrition from intrinsic vessels. Extrinsic vessels supply the intrinsic system and are under adrenergic control. Fascicles are collections of axons contained within perineurium. Fascicles are separated by connective tissue and surrounded by epineurium. Illustration by Jennifer Gentry. ©American Society of Regional Anesthesia and Pain Medicine.

palmar base of the index finger, whereas another pinch at the palmar base of the little finger assesses the ulnar nerve. Movement of the little finger during infraclavicular block (ICB) helps to identify which cord is being stimulated. With the arm adducted, movement of the little finger medially toward the body indicates medial cord stimulation, whereas lateral movement away from the body indicates lateral cord stimulation. The posterior cord is identified when the little finger moves posteriorly.¹⁴

Vascular Elements

In addition to the neural elements, several vascular structures have profound clinical importance as anatomic landmarks or structures to avoid. The vertebral artery travels cephalad from its origin in the subclavian artery; at the C6 level, it enters the vertebral foramen located in each of the cervical vertebral transverse processes. As the cervical roots of the brachial plexus leave the intervertebral foramina, they course immediately posterior to the vertebral artery,¹⁵ thereby offering an interposed portal for potential intravascular injection, particularly if the anesthetizing needle courses anterior and medial to the anterior scalene muscle (Fig. 1). The external jugular vein often overlies the interscalene groove at the level of C6 but is not a reliable anatomic marker. The subclavian artery lies alongside the brachial plexus as they course over the first rib (Figs. 1, 2, 7). Here, the trunks/divisions of the brachial plexus lie posterior, cephalad, and eventually lateral to the subclavian artery,¹⁵ which presents a valuable anatomic relationship during placement of supraclavicular block. The cords are defined by their lateral,

Cutaneous Sensory Distribution

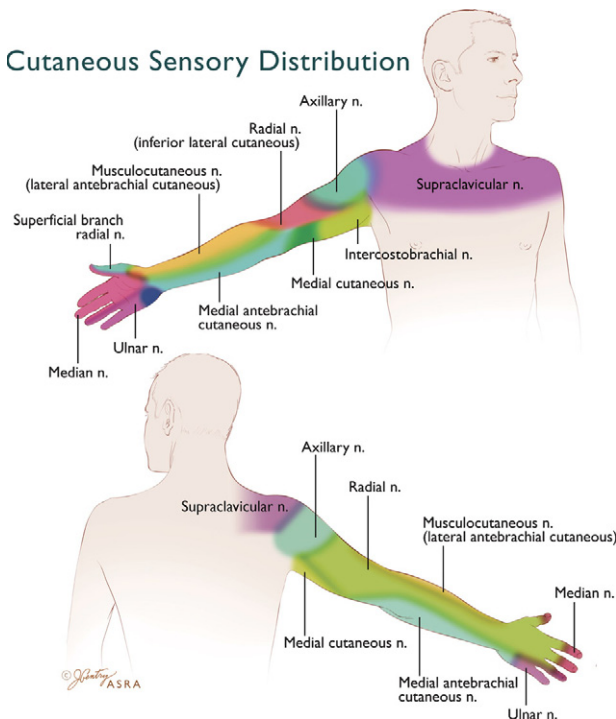


FIGURE 6. Cutaneous sensory distribution of the upper extremity. Terminal nerves of the brachial plexus provide sensory innervation to the arm. The sensory distribution of these nerves is variable and overlapping—as depicted by blended colors as the zones converge. Illustration by Jennifer Gentry. ©American Society of Regional Anesthesia and Pain Medicine.

posterior, or medial relationship to the second part of the axillary artery, although their actual position varies significantly between individuals.¹⁶ In the base of the axilla, the axillary artery occupies its characteristic location relative to the terminal branches of the plexus—anterior to the radial nerve, posteromedial to the median nerve, and posterolateral to the ulnar nerve. However, significant individual variation occurs^{17,18} (Fig. 8). Of practical importance, nerve-vascular relationships are affected by changes in the arm position and/or applied external pressure during block performance.

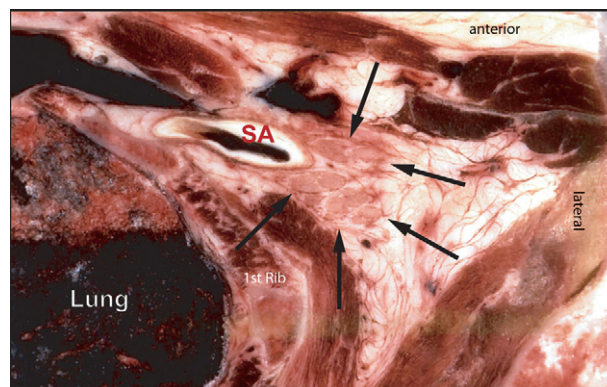


FIGURE 7. Cryomicrotome section of the right supraclavicular area. The brachial plexus (arrows) lies posterior and lateral to the subclavian artery (SA). Note the proximity of the lung. There is no evidence of a defined brachial plexus sheath in this section. Cryomicrotome courtesy of Quinn H. Hogan, MD.

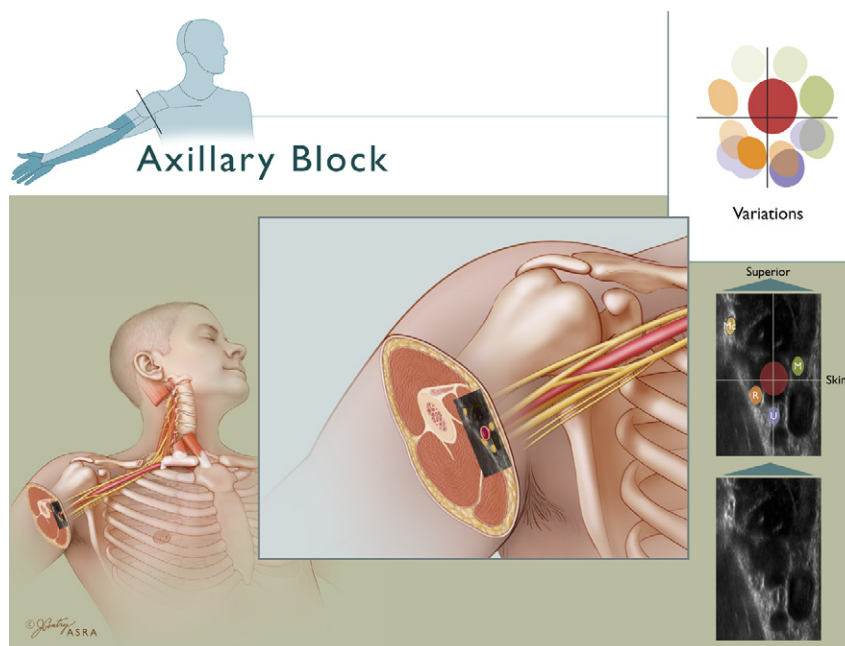


FIGURE 8. Axillary block. Top left insert depicts the expected distribution of anesthesia consequent to AXB. The 4 terminal nerves are drawn in their classic relationship to the axillary artery, which in turn is correlated to ultrasonic anatomy that shows the hyperechoic nerves. Note: To correlate with the illustration, the ultrasound inset is rotated 90 degrees clockwise from the way it is normally viewed in a patient. There is significant variation in how the terminal nerves relate to the axillary artery. The upper right inset depicts these variations as color-coded nerves in various positions around the artery (radial nerve = orange, ulnar nerve = blue, median nerve = green). The color saturation correlates with the expected frequency of the nerve residing in a specific location—the deeper the saturation, the more frequently the nerve is found in that position.¹⁸ The musculocutaneous nerve (MC) lies in the fascial plane between the coracobrachialis and biceps muscles. Illustration by Jennifer Gentry. ©American Society of Regional Anesthesia and Pain Medicine.

Tissues Surrounding the Brachial Plexus

The precise architecture of those tissues surrounding the brachial plexus is incompletely understood and highly debated. Recent research with opposing viewpoints has reignited interest in this long-standing controversy, which centers on the structural integrity and function of a connective tissue-based “sheath” versus a more rigid “axillary tunnel” defined by surrounding muscle and bone. The divergent views on this topic are partially explainable by the difficulties encountered in correlating cadaveric studies with fresh tissue observations^{19,20} and with reconciling imaged-based findings with clinical observations.

Similar to other neurovascular bundles throughout the body, portions of the brachial plexus are embedded within connective tissues of varying density (Figs. 2, 7, and 9). Some investigators described the connective tissues as forming a multicompartimental structure comprising thin layers of fibrous tissue, which in cadavers are permeable to dye or latex.^{17,21} Earlier investigators proposed the concept of a tubular sheath of high structural integrity, which contains only nerves and vessels.^{22,23} These concepts have been subsequently refined over nearly a half-century, in part to reconcile clinical observations of actual local anesthetic blockade with observations related to the surrounding tissue architecture.^{17,21,24–28} The presence of a well-defined sheath varies along the course of the brachial plexus; for example, there is no evidence of a substantial sheath on cryomicrotome sections of the supraclavicular region (Fig. 7).²⁹ Yet, other cadaveric studies note a distinct fibrous structure filled with loose connective tissue. Between the epineurium and the connective tissue lies a potential space that may offer a pathway of less resistance that promotes longitudinal, rather than circumferential, spread of local anesthetic.²⁸ This often made

clinical observation that local anesthetic is less likely to spread circumferentially²⁷ may also reflect where it is injected. For example, some investigators interpret the terminal nerves at the base of the axilla as traveling independently of each other in their own connective tissue envelopes, which potentially limit

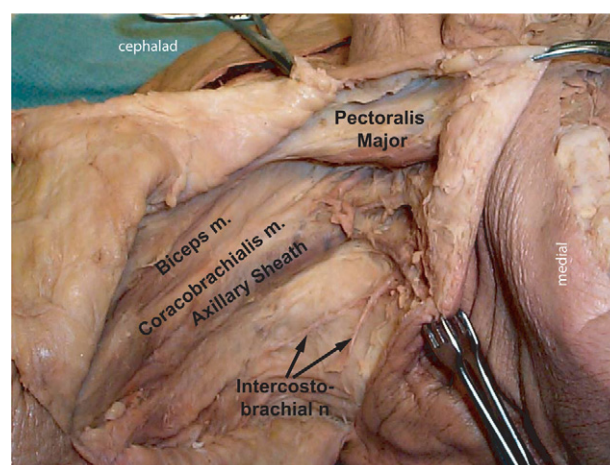


FIGURE 9. Dissection of the right axilla. The brachial plexus is contained within connective tissue of the axillary sheath and lies inferior to the biceps and coracobrachialis muscles. At this level, the musculocutaneous nerve is likely within the belly of the coracobrachialis muscle or the fascial plane between it and the biceps. Note that the intercostobrachial nerve is not part of the plexus. Photo courtesy of Quinn H. Hogan, MD.

TABLE 1. Comparison of Regional Anesthetic Approaches to the Brachial Plexus

Author	No. Subjects	Approach	Technique	No. Injections	Criteria for Success	Percentage of Success (<i>P</i>)
Supraclavicular vs axillary approach						
Brand and Papper ³²	230	SCB	Paresthesia	NR	A	84
	246	AXB				92 (NS)
Thompson et al ³³	1913	SCB	Paresthesia	NR	A	83
	665	AXB				85 (NS)
Moorthy et al ³⁴	120	SCB	PNS	1	A	72
		AXB		NR		86 (NS)
Kapral et al ³⁵	40	SCB	Catheter	1	NR	95
		AXB		1		75 (NS)
Fleck et al ³⁶	40	SCB	PNS	1	A	80
		AXB	Paresthesia/ Transarterial	1		65 (NS)
Infraclavicular vs axillary approach						
Kapral et al ³⁷	40	ICB	PNS	1	N	90
		AXB		1		85 (NS)
Koscielniak-Nielsen et al ³⁸	60	ICB	PNS	2	N	53
		AXB		4		83 (<i>P</i> = 0.003)
Sia et al ³⁹	100	ICB	PNS	4	N	89
		AXB		4		91 (NS)
Fleischman et al ⁴⁰	100	ICB	PNS	1	N	100
		AXB		3		80 (<i>P</i> = 0.04)
Deleuze et al ⁴¹	100	ICB	PNS	1	N	90
		AXB		3		88 (NS)
March et al ⁴²	100	ICB	PNS	3	N	94
		AXB (humeral)		4		79 (<i>P</i> < 0.5)
Minville et al ⁴³	120	ICB	PNS	2	N	92
		AXB (humeral)		4		95 (NS)
Ertug et al ⁴⁴	30	ICB	PNS	1	A	80
		(catheter) AXB (catheter)		1		87 (NS)
Heid et al ⁴⁵	60	ICB	PNS	1	N	Distribution of analgesia (NS)
		AXB (catheter)		1		
Koscielniak-Nielsen et al ⁴⁶	60	ICB	PNS	1	N	85
		AXB		4		92 (NS)
Minville et al ⁴⁷	104	ICB	PNS	3	N	90
		AXB (humeral)		4		94 (NS)
Niemi et al ⁴⁸	60	ICB	PNS	1	N	90
		AXB				87 (NS)
Comparisons of other approaches						
Riegler ⁴⁹	34	AXB	PNS	1	A	79
	79	SCB				97
	43	ISB				91 (NS)
Schroeder et al ⁵⁰	247	AXB	Multiple techniques	NR	A	89*
	59	SCB				78
	24	ISB				75 (<i>P</i> < 0.03)*
Fanelli et al ⁵¹	1650	AXB	PNS	<7	A	93
	171	ISB		<3		94 (NS)
Arcand et al ⁵²	80	ICB	US	1	N	64
		SCB		1		71 (NS)
DeJose et al ⁵³	80	ICB	US	Multiple	A	88
		SCB				95 (NS)

(Continued on next page)

TABLE 1. (Continued)

Author	No. Subjects	Approach	Technique	No. Injections	Criteria for Success	Percentage of Success (P)
Major variations of classic approaches						
Bouaziz et al ⁵⁴	60	AXB	PNS	2	N	58
		AXB (humeral)		4		90 (P < 0.05)
Dalens et al ⁵⁵	120	Parascapene	PNS	1	A	97
		SCB				88 (NS)
Pippa et al ⁵⁶	80	TCB	Fascial click	1	A	87
		AXB (classic)	P			77 (NS)
Pippa ⁵⁷	60	SCB	PNS	1	A	86
		PCN				66 (NS)
Koscielniak-Nielsen et al ⁵⁸	80	AXB	PNS	4	A	75
		AXB (humeral)		4		57 (NS)
Bigeleisen and Wilson ⁵⁹	202	ICB (lateral)	US	3	N	100
		ICB (medial)		3		94 (NS)
Rettig et al ⁶⁰	80	ISB	PNS	1	N	83
		ISB (posterior)		1		90 (NS)
Fuzier et al ⁶¹	90	AXB	PNS	2	N	80
		AXB (humeral)		4		91 (NS)

*(AXB versus SCB and ISB).

Brachial plexus blocks: AXB, axillary; SCB, supraclavicular; ISB, interscalene; ICB, infraclavicular; ISCM, intrasternocleidomastoid; PCN, proximal cranial needle SCB; TCB, transcoracobrachial; PNS, peripheral nerve stimulation. Criteria for successful block: N, evaluation of individual nerve function; A, need for anesthesia supplementation. NR, not reported; NS, not significant.

circumferential diffusion but facilitate longitudinal spread of local anesthetic. Others suggest that the interlinking of trunks, divisions, and cords potentially creates interconnecting channels that promote wider spread of local anesthetics injected near the apex of the axilla.²⁵ Yet another viewpoint is that rather than connective tissue structures, it is the rigid anatomy comprising the surrounding bony and muscular structures (the "axillary tunnel") that plays a vital role in directing the flow of injected solutions. This concept likewise is consistent with clinical observation of longitudinal local anesthetic spread.^{25,26}

Despite ongoing debate regarding the structural components of the tissues surrounding the brachial plexus, it is clear that the nerves are embedded in connective tissue. The functional interactions of connective tissues with individual nerves, of the brachial plexus with rigid elements of the axillary tunnel, and the level at which the local anesthetic is injected may all influence distribution. That these factors seemingly promote either longitudinal or circumferential spread of local anesthetic correlates functionally with the clinical observation that anesthetic success at the more distal blocks is improved by multiple, rather than single, injections.^{30,31}

APPROACHES TO THE BRACHIAL PLEXUS

Throughout this review, we define *approach* as the level along the brachial plexus that the block needle is placed, for example, the interscalene or the axillary approach. We define *technique* as that technical aspect of how the block is actually performed, for example, how the nerve is localized or how many injections are made around the nerve.

Clinicians have approached the nerves of the upper extremity at every anatomic division of the brachial plexus, from the nerve roots to individual terminal branches (Fig. 4). Despite the existence of a myriad of techniques for each of these approaches, there are few clinical comparisons of block success rate, and less still of latency or duration as a function of the

chosen anesthetic approach and/or technique (Table 1). Indeed, the very definition of success varies widely. Some studies compare successful blockade of all nerves as the criteria for success, whereas others compare adequacy for the intended surgical procedure (ie, need for general anesthesia). This section summarizes the relatively sparse data pertaining to brachial plexus approaches. No attempt was made to describe the actual performance of individual blocks; instead, the reader is encouraged to seek this information in the source document at www.asra.com or refer to the cited original descriptions.

Interscalene Block

The principal indication for an ISB is surgery of the shoulder (Fig. 10). Three primary variations of this approach exist—the classic approach of Winnie et al,⁶² a modified lateral approach,⁶³ and the transmiddle scalene ultrasound-guided approach.⁶⁴ Local anesthetic spread after interscalene administration extends from the distal roots/proximal trunks and follows a distribution to the upper dermatomes of the brachial plexus⁶⁵ that consistently includes the (nonbrachial plexus) supraclavicular nerve (C3-C4), which supplies sensory innervation to the cape of the shoulder.⁶⁶ An ISB using paresthesia or PNS localization technique often functionally spares the lower trunk (primarily the ulnar nerve), which remains unanesthetized in 30% to 50% of blocks.⁶⁷ More inclusive anesthesia of the lower trunk is possible with ultrasound-guided techniques.⁶⁸ Several technical caveats pertain to ISB. First, paresthesia or motor response to the arm or anterior shoulder is appropriate for shoulder surgery.^{69,70} Second, the observation of unintended evoked motor responses may help refine needle placement. Contraction of the diaphragm indicates phrenic nerve stimulation and too anterior placement of the needle tip. Rhomboid muscle movement indicates stimulation of the dorsal scapular nerve (C5) and needle placement that is too posterior.⁷¹ Third, the roots and trunks normally appear as hypoechoic structures within the interscalene groove when visualized with

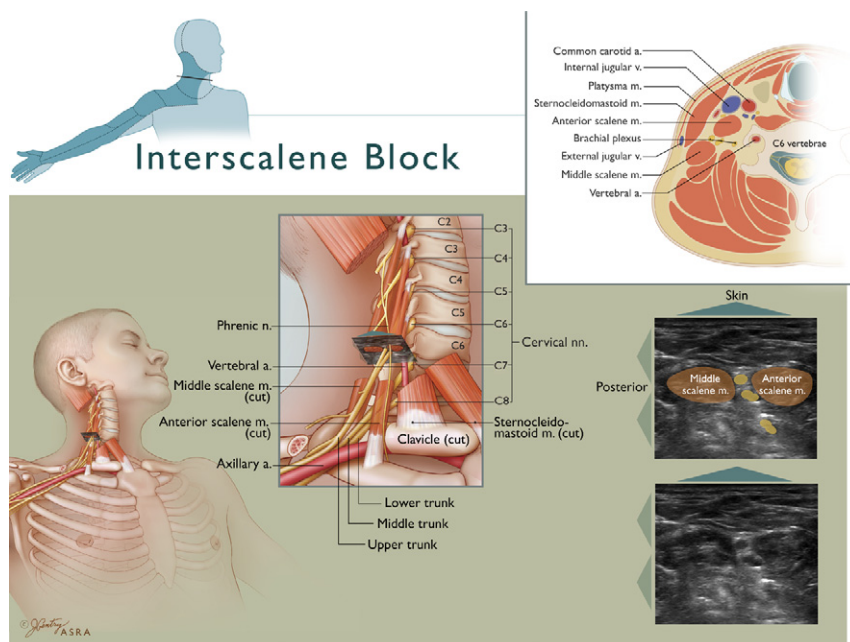


FIGURE 10. Interscalene block. The upper left inset depicts the expected distribution of anesthesia consequent to ISB. The roots converge to form trunks at the medial border of the middle scalene muscle. The vertebral artery lies medial to the anterior scalene muscle and anterior to the plexus. The classic ultrasound view depicts the hypoechoic upper roots (most likely C5–C7) stacked on each other, within the interscalene groove. The upper right inset depicts the closeness of the brachial plexus to major arteries and the spinal canal. Illustration by Jennifer Gentry. ©American Society of Regional Anesthesia and Pain Medicine.

ultrasound, but roots sometimes pass through the scalene muscles.^{8,9} Finally, PNS- or paresthesia-guided ISB is typically a single-injection technique, whereas ultrasound-guided ISB uses multiple injections to ensure local anesthetic spread around the plexus.^{62,64,72}

Cervical Paravertebral Blocks

Posterior approaches to the brachial plexus were popularized by Pippa et al⁷³ and more recently refined by Boezaart et al.⁷⁴ Cervical paravertebral block is primarily used for shoulder surgery.^{57,74,75} Observational studies have shown 98% overall success with this approach.⁷⁶ The posterior approach of Boezaart et al⁷⁴ is comparable to the lateral approach of Winnie et al in terms of block success and side effects.⁶⁰ The cervical paravertebral block causes less motor block⁷⁴ and greater ease of perineural catheter placement⁷⁵ as compared with traditional interscalene approaches. Several ultrasound-guided posterior approaches to the brachial plexus have been described.^{77,78}

Intersternocleidomastoid Block

The intersternocleidomastoid block (ISCMB) is a variation of the supraclavicular approach and is indicated for hand and arm surgery. The ISCMB involves significant modifications from other supraclavicular approaches, including directing the needle laterally between the heads of the sternocleidomastoid muscle.⁷⁹ This technique has been advocated for its ease of catheter insertion and theoretically lowers the risk of pneumothorax, although the latter claim is unsubstantiated. The needle, by passing behind the clavicular head of the sternocleidomastoid muscle, passes near the apex of the pleura as it progresses toward the brachial plexus. Intersternocleidomastoid block using a catheter technique fails to achieve ulnar anesthesia in 15% of patients.⁷⁹

Supraclavicular Block

The usual indications for supraclavicular plexus block are surgery of the hand and arm (Fig. 11). It can also be used for shoulder surgery but may require supplementation of the supraclavicular nerve (C3–C4) to ensure anesthesia of the cape of the shoulder. Three primary variations of this block have been described—the subclavian perivascular approach,²³ the “plumb-bob” approach,⁸⁰ and an ultrasound-guided approach.⁸¹ This block is performed where the brachial plexus is presented most compactly—at the distal trunk/proximal division level. This compactness may explain the block’s historical reputation for providing short latency and complete, reliable anesthesia for upper extremity surgery,⁸⁰ although confirmatory data do not exist. Several technical caveats apply to supraclavicular plexus block. First, the risk of pneumothorax may be substantially reduced by technical modifications of the block, which are discussed in the section on pneumothorax. Second, stimulation of the middle trunk (hand contraction or paresthesia) has been associated with higher success rates for hand surgery.^{82,83} Third, if ultrasound-guided regional anesthesia (UGRA) is used, concomitant PNS is redundant for improving block success.⁸⁴ Finally, in contrast to the contention that UGRA facilitates blockade with smaller volumes of local anesthetic, the minimum volume required for UGRA supraclavicular blockade in 50% of patients is 23 mL, which is similar to recommended volumes for traditional nerve localization techniques.⁸⁵

Infraclavicular Block

Surgeries of the hand and arm are indications for ICB, which is performed at the level of the cords (Fig. 12). As compared with the supraclavicular approaches, ICB has less impact on pulmonary function but is more likely to spare the radial nerve distribution if a single injection is used.⁵² The

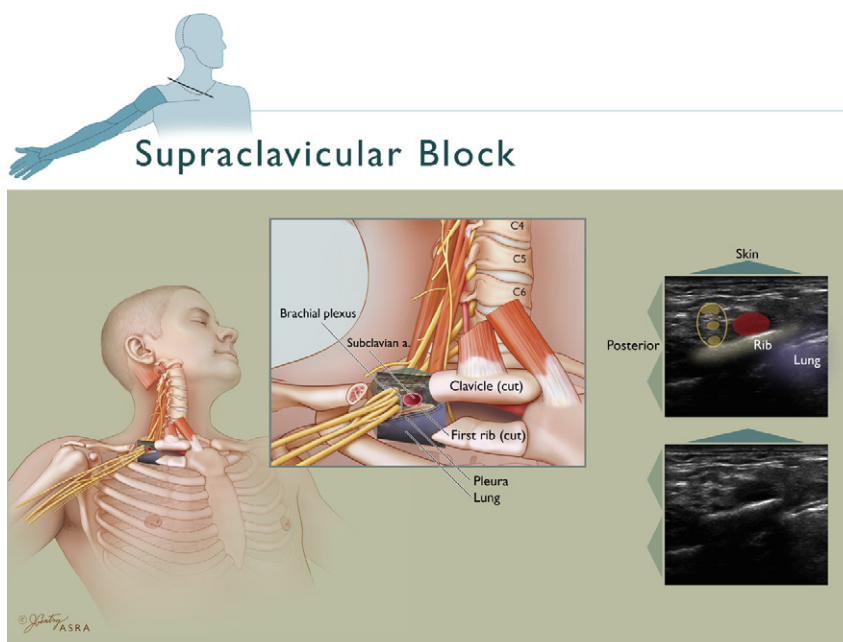


FIGURE 11. Supraclavicular block. Inset depicts the expected distribution of anesthesia consequent to supraclavicular block. The trunks begin to diverge into the anterior and posterior divisions as the brachial plexus courses below the clavicle and over the first rib. The plexus is posterior and lateral to the subclavian artery, and both overlie the first rib in close approximation to the pleura and lung. The classic ultrasound view depicts the hypoechoic trunks bundled together lateral to the subclavian artery and over the first rib, which casts an acoustic shadow as the ultrasound beam is attenuated by bone. Note that the pleura does not impede the passage of the ultrasound beam to the same extent. Illustration by Jennifer Gentry. ©American Society of Regional Anesthesia and Pain Medicine.

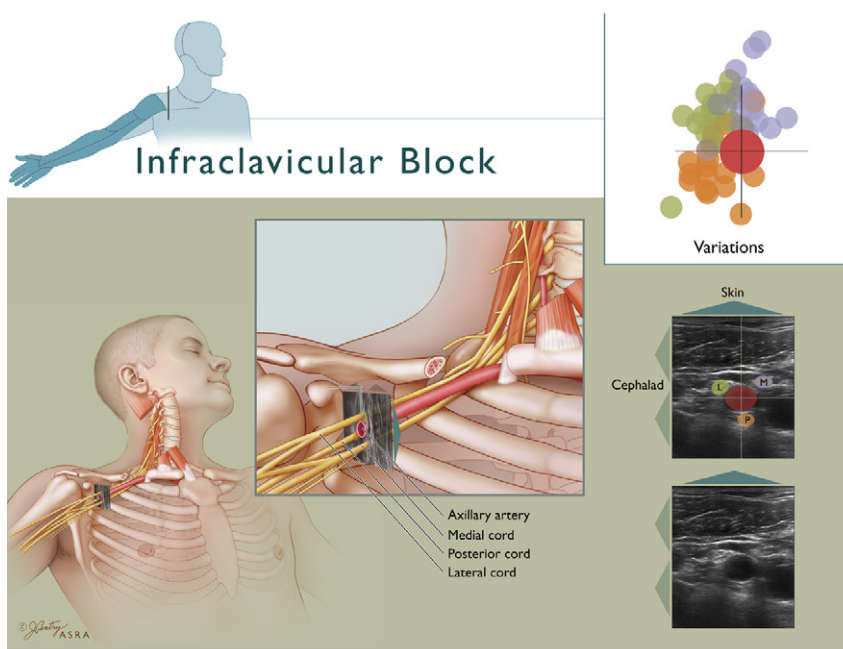


FIGURE 12. Infraclavicular block. Inset depicts the expected distribution of anesthesia consequent to ICB. The cords take on their characteristic position lateral, posterior, and medial to the second part of the axillary artery in this illustration of the coracoid approach. The medial cord frequently lies between the axillary artery and vein (4-o'clock). There is considerable variation in the relationship of the artery to the cords,¹⁶ as depicted by the color-coded cords in the upper right inset (lateral cord = green, medial cord = blue, posterior cord = orange). The color saturation correlates with the expected frequency of the cord residing in a specific location—the deeper the saturation, the more frequently the cord is found in that position. Illustration by Jennifer Gentry. ©American Society of Regional Anesthesia and Pain Medicine.

infraclavicular approach provides more consistent anesthesia of the axillary and musculocutaneous nerves than the axillary approach, although often at the expense of longer latency.^{38,86} There are 3 primary variations of the ICB (from most lateral to medial)—the coracoid approach,^{87,88} the lateral sagittal approach,⁸⁹ and the vertical approach.⁹⁰ The coracoid approach seems to be the most popular North American variation, perhaps because the anatomic landmarks are straightforward and the block's lateral entry point most reduces the possibility of pneumothorax and hemidiaphragmatic paresis (HDP).⁹¹ Technical caveats for the ICB include the following: first, although the lateral, posterior, and medial cords are named by their relationship with the second part of the axillary artery, the cords are likely to be anterior to the artery at the more medial approaches to the block. At the coracoid level, substantial variation exists in where the cords actually reside in relation to the artery.¹⁶ Second, when using a PNS, a double-injection technique increases success as compared with a single-injection technique, particularly when one of the injections is near the posterior cord.^{52,92–95} Third, acceptance of a musculocutaneous motor response in lieu of a more distal lateral cord response is associated with less successful ICB, because the musculocutaneous nerve frequently branches from the lateral cord more proximally (Fig. 4). Finally, when using UGRA, achieving local anesthetic spread around the axillary artery,^{96,97} particularly posterior to the artery,⁹⁵ improves success.

Axillary Block

The axillary block (AXB) is indicated for hand and arm surgery and remains a widely used, studied, and modified approach to the brachial plexus (Fig. 8). All techniques—paresthesia-seeking,⁹⁸ nerve-stimulating,⁵⁴ perivascular,⁹⁹ transarterial,¹⁰⁰ and ultrasound-guided¹⁰¹—work at the level of the terminal nerves. Successful blockade of individual nerves varies from 60% to nearly 100%, depending on the technique. Several technical caveats apply to AXB. First, all AXB techniques rely

on the relationship of the terminal nerves to the axillary artery, which is the primary surface landmark for this block. Significant variation exists regarding the position of the nerves relative to the axillary artery (Fig. 8).^{17,18} Second, multiple injections are superior to single injection for the axillary approach.^{27,30,102} Radial nerve identification seems to be most important for successful block, whereas ulnar nerve identification is least important and unnecessary if the other nerves have been localized.^{102–104} With regard to the midaxillary approach, obtaining 4 nerve stimulations significantly increased overall success rate (91% vs 76%) and reduced time for readiness for surgery when compared with eliciting 3 separate paresthesias and blindly supplementing the musculocutaneous nerve. However, in this study, only blockades of the radial nerve and the musculocutaneous nerve (blocked separately) were statistically different, suggesting that the techniques may be more similar than dissimilar.¹⁰⁵ When using a 4-nerve-stimulation, mid-humeral approach, blocking the radial nerve before the ulnar nerve improves subsequent nerve localization.¹⁰⁶ Third, the relationship of the musculocutaneous nerve to the brachial plexus deserves special consideration, because it courses away from the axillary artery early and resides within the body of the coracobrachialis muscle or the fascial layers between the coracobrachialis and the biceps muscles. Anesthesia of the musculocutaneous nerve is best ensured by a separate injection into the belly of the coracobrachialis muscle^{99,107} or by using direct ultrasound guidance.¹⁰⁸

Accessory Upper Extremity Nerve Blocks

Block of the Supraclavicular Nerves of the Superficial Cervical Plexus

The supraclavicular nerves are branches of the superficial cervical plexus (C3–C4) and provide cutaneous innervation of the cape of the shoulder (Fig. 13). Although not part of the brachial plexus, they are consistently blocked with the

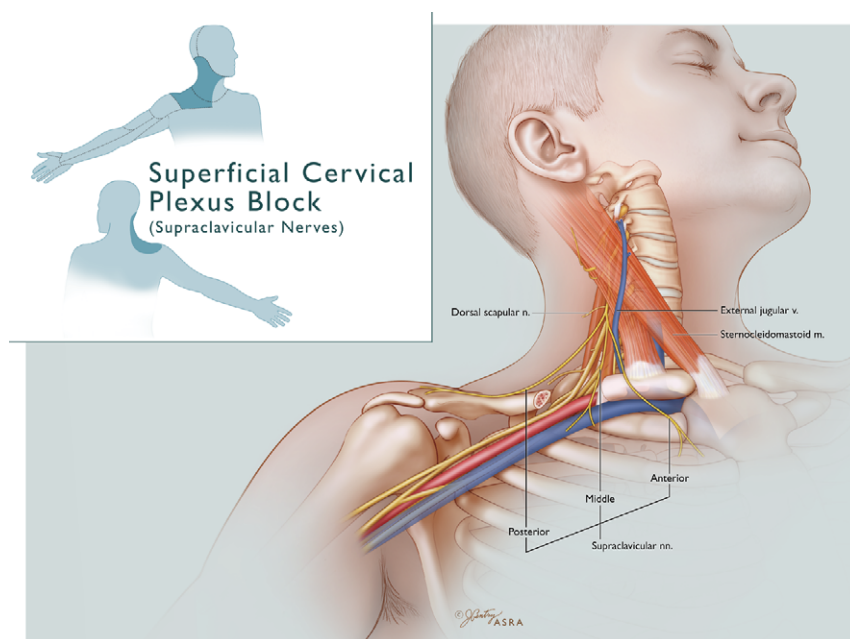


FIGURE 13. Block of the supraclavicular branches of the superficial cervical plexus. Inset depicts the expected distribution of anesthesia consequent to supraclavicular nerve block. The 3 supraclavicular nerve branches (C3–C4) provide cutaneous innervation to the cape of the shoulder. Illustration by Jennifer Gentry. ©American Society of Regional Anesthesia and Pain Medicine.

interscalene approach.⁶⁶ However, they may require separate blockade if shoulder surgery is contemplated using more distal approaches to the brachial plexus.¹⁰⁹

Suprascapular Nerve Block

The suprascapular nerve (C5-C6) provides sensory innervation to the posterior/superior 70% of the shoulder joint, the acromioclavicular joint, and to the anterior axilla in ~10% of patients¹¹⁰ (Fig. 14). This nerve branches from the upper trunk (Figs. 1 and 4) and is typically anesthetized during an ISB. Suprascapular block is most useful as an adjunct to general anesthesia or as a rescue block for posterior shoulder pain or anterior arthroscopic port pain in the setting of an incomplete ISB. Approaching the suprascapular spine from a cephalad-to-caudad direction, rather than posterior-to-anterior, likely reduces the risk of pneumothorax by avoiding needle translocation through the suprascapular notch and into the pleura.

Intercostobrachial Nerve Block

Because it is not part of the brachial plexus but rather is a branch of the second intercostal nerve (Fig. 9), it is not anesthetized by plexus techniques.⁶⁷ The intercostobrachial nerve (T2) requires separate blockade for surgeries of the medial upper arm or axilla. Placement of intercostobrachial nerve block may prevent tourniquet sensation within the T2 distribution, but its importance in reducing tourniquet pain is controversial¹¹¹ because tourniquet pain is likely mediated by ischemia and distal tissue compression in addition to local sensation.¹¹²

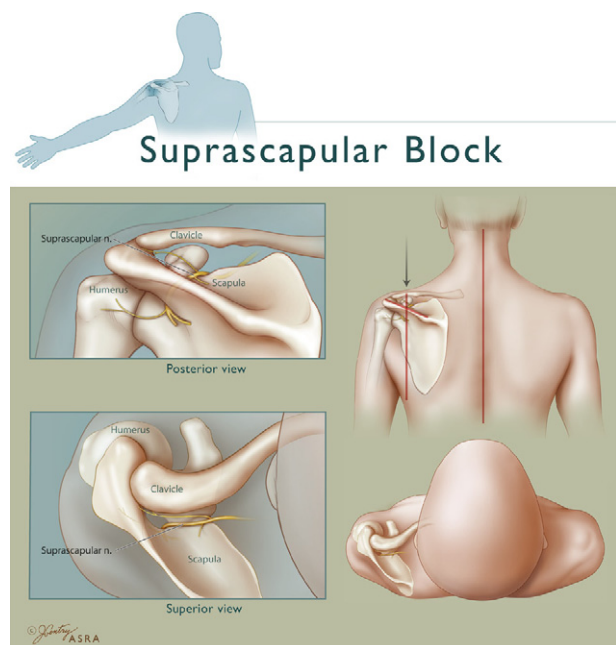


FIGURE 14. Suprascapular nerve block. Inset depicts the expected distribution of anesthesia consequent to SSNB—the posterior 70% of the shoulder joint and the acromioclavicular joint. The nerve exits through the suprascapular notch. A cephalad-to-caudad needle trajectory (arrow) should reduce the risk of entering the notch and causing a pneumothorax. Illustration by Jennifer Gentry. ©American Society of Regional Anesthesia and Pain Medicine.

Antebrachial Cutaneous Blocks

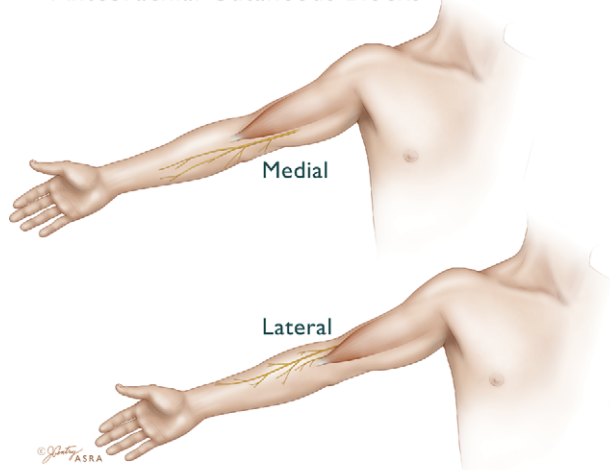


FIGURE 15. Medial and lateral antebrachial cutaneous nerve blocks. The medial antebrachial cutaneous nerve branches from the medial cord to innervate the ulnar volar forearm. The lateral antebrachial cutaneous nerve is the sensory terminus of the musculocutaneous nerve; it innervates the radial volar forearm. Illustration by Jennifer Gentry. ©American Society of Regional Anesthesia and Pain Medicine.

Lateral and Medial Antebrachial Cutaneous Nerve Blocks

The medial antebrachial cutaneous nerve is a branch of the medial cord; it innervates the ulnar volar forearm (Fig. 15). The lateral antebrachial cutaneous nerve is the cutaneous termination of the musculocutaneous nerve that provides sensation to the radial volar forearm. These blocks are useful as a primary anesthetic for superficial forearm surgery or for safely rescuing an incomplete proximal plexus blockade because they do not seek needle-to-nerve proximity.^{109,113}

Selective Nerve Blocks at the Elbow, Forearm, or Wrist

Blockade of individual nerves at the elbow or wrist¹⁰⁹ is limited by the need to block several nerves for most hand and forearm surgical indications, by tourniquet considerations, and by limited evidence that suggests blocking partially anesthetized nerves to rescue failed proximal plexus blockade may increase the risk of nerve injury.^{114,115} Ultrasound-guided techniques for selective terminal nerve blockade in the upper arm or forearm have been described.^{108,116–118} Although comparative data are limited, recent studies have shown ultrasound-guided wrist blocks to be as efficient as PNS-guided ones.¹¹⁹

Comparative Effectiveness of Brachial Plexus Approaches

Four major randomized controlled trials (RCTs) comparing intraoperative brachial plexus blockade to fast-track general anesthesia have shown superior analgesia with the regional technique but no further outcome benefits after 24 hrs.^{120–123} Likewise, 8 of 9 comparisons of continuous perineural techniques to single-shot upper extremity regional anesthetic techniques have supported the positive role of continuous blocks in routine and advanced patient management (Table 2).^{124–127,129,130,132,133} The beneficial effects of

TABLE 2. Comparison of Single-Shot and Continuous Techniques

Author	No. Subjects	Comparison	Outcome Improvement With Continuous Technique
Klein et al ¹²⁴	40	ISB (0.5% ropi+epi) ISB+cISB (0.2% ropi)	Less pain and opioid use; more frequent need for no opioids
Salonen et al ¹²⁵	60	AXB (0.75% ropi) AXB+cAXB (0.1% ropi) AXB+cAXB (0.2% ropi)	No differences in pain or opioid use; however, subjects had minimally painful surgery
Ilfeld et al ¹³²	30	ICB (1.5% mepi+epi) ICB = cICB (0.2% ropi)	Less pain, opioid use, and nausea/pruritus; better patient satisfaction and sleep
Ilfeld et al ¹²⁶	20	ISB (1.5% mepi+epi) ISB+cISB (0.2% ropi)	Less pain, opioid use, and nausea/pruritus; better patient satisfaction and sleep
Delaunay et al ¹²⁷	30	ISB+subacromial wound infusion ISB+cISB	Less pain, opioid use, and less local anesthetic use; more mild respiratory complaints
Ilfeld et al ¹³³	30	cISB overnight cISB until POD 4	Less pain and opioid use; earlier achievement of discharge criteria
Capdevila et al ¹²⁹	40	ISB (0.5% ropi) ISB+cISB (0.2% ropi)	Less pain, opioid use, nausea and vomiting, sleep disturbance, dizziness; earlier ambulation and increased daily activity
Kean et al ¹³⁰	8	ISB (0.5% levobupi) ISB+cISB (0.25% levobupi)	Less pain and opioid use; higher satisfaction
Hofmann-Kiefer et al ¹³¹	87	ISB (0.75% ropivacaine) ISB+cISB	Less pain, opioid use, nausea and vomiting; no difference in joint mobility or rehabilitation

AXB indicates axillary; ISB, interscalene; ICB, infraclavicular; cISB, continuous interscalene; GETA, general endotracheal anesthesia. Agents: LIDO, lidocaine; CP, chloroprocaine; BUPI, bupivacaine; ropi, ropivacaine; ISO, isoflurane; DES, desflurane. LMA, laryngeal mask airway; POD, postoperative day.

continuous blocks are improved by the preemptive use of multimodal analgesic pathways.¹³⁴ The following subsections examine ideal regional anesthesia and analgesia approaches for specific surgical indications.

Analgesia for Shoulder Surgery

Single-shot ISB is generally considered the standard to which other methods for analgesia after shoulder surgery are compared. A suprascapular nerve block (SSNB) decreased pain and hospital stay after shoulder arthroscopy performed under general anesthesia¹³⁵ but did not improve outcomes in patients undergoing open shoulder surgery with combined general/interscalene anesthesia plus supplemental SSNB.¹³⁶ An SSNB is superior to intra-articular injection after shoulder arthroscopy but is inferior to ISB.¹³⁷ When directly compared in another study, ISB gave better early analgesia than intra-articular injection but similar analgesia at 24 hrs.¹³⁸ The combination of SSNB and an axillary nerve block has also received preliminary study for analgesia after shoulder surgery.^{139,140} Interscalene block is superior to subacromial bursa block.¹⁴¹ Perhaps most important, continuous brachial plexus blocks consistently provide superior analgesia with fewer side effects than either continuous subacromial infusion¹²⁷ or single-shot ISB, while promoting earlier hospital discharge and possibly improving rehabilitation after major surgery.^{126,129,133,142–146}

Anesthesia for Arm and Hand Surgery

Regional anesthesia for hand and arm surgery has been shown in RCTs to be superior to general anesthesia in terms of analgesia and reduced opioid-related side effects during the first 24 hrs after surgery.^{121,123} The best regional anesthesia approach for these patients is less well defined. For elbow surgery, a retrospective comparison of interscalene, supraclavicular, and AXBs found success rates of 75% versus 78% versus 89%, respectively.⁵⁰ For hand and forearm surgery, studies from more than 10 years ago failed to find a difference between the

axillary and supraclavicular approaches (Table 1). There are no data to compare the increasingly frequent use of ultrasound-guided supraclavicular block to AXB. A single study failed to find significant difference in block success with ultrasound-guided infraclavicular versus supraclavicular plexus blocks.⁵² As knowledge of the ideal needle position, number of injections, and ultrasound guidance has refined the technique of ICB, recent comparative studies consistently show it equal or superior to the axillary approach.^{40,41,43–46,48} Axillary block typically has a shorter latency than the midhumeral block, but the comparative success rates between them vary greatly—showing higher success with the axillary,⁵² the midhumeral,⁵⁴ or no difference between the 2 blocks.^{39,58,61}

TECHNICAL ASPECTS OF BRACHIAL PLEXUS BLOCK

Methods of Nerve Localization

Key to regional anesthesia is localizing the block needle sufficiently close to the nerve to accomplish successful neural blockade but not so close as to injure the nerve. This section summarizes information that compares various methods of nerve localization. As single-injection infraclavicular and AXBs fall into disfavor, so does reliance on the perception of fascial clicks, which are poor indicators of needle-to-nerve proximity.^{17,147,148} Novel use of surface localization techniques such as skin nerve stimulation has emerged.^{149,150} In particularly challenging patients, such as those with tumor near or within the brachial plexus, computed tomography is useful for nerve localization.¹⁵¹

Paresthesia Versus Peripheral Nerve Stimulation

Although paresthesia seems to be a more sensitive indicator of needle-to-nerve proximity than is a PNS-generated motor response,^{152,153} the explanation for this phenomenon is unclear.^{154,155} Needle localization by either paresthesia or

PNS seems to be equally efficacious—studies that directly compare these 2 modalities note similar success rates (70%–90%), albeit these rates are generally lower than reported by others in noncomparative studies.^{156,157} When using a PNS, obtaining an appropriate motor response at 0.5 to 0.8 mA or less has been associated with a greater likelihood of successful blockade.^{152,158,159}

Transarterial Injection Versus Paresthesia or Peripheral Nerve Stimulation

When compared with a 4-nerve stimulation technique, the 2-injection transarterial technique for AXB was less successful (90% vs 62%, respectively).^{160,161} A noncomparative study of a single large-volume (50 mL) transarterial injection technique reported 99% success,¹⁰⁰ although 2 injections were actually made “in the same location posterior to the axillary artery.”

Transarterial Versus Perivascular Techniques

Whether by “fanning” local anesthetic on either side of the axillary artery or by stable-needle transarterial injection(s), perivascular AXB techniques are associated with reasonable (88%–99%) success and low complication rates.^{99,100,115} Although a noncomparative study¹⁰⁰ reported 99% success with 2 injections posterior to the artery, a comparative study reported faster and more complete block by splitting the injection anterior and posterior to the artery, rather than using a single injection.¹⁶²

Peripheral Nerve Stimulation Versus Ultrasound Guidance

Ultrasound studies have consistently demonstrated that the block needle tip can be in close proximity to a nerve without

accompanying paresthesia or motor response even at high current.^{147,163–165} Because motor response to PNS can be variable when the needle tip is observed to be on the surface of or even within the nerve,^{164,166} ultrasound guidance is theorized to provide a more definitive end point of needle-to-nerve proximity. Indeed, recent studies of ICB have demonstrated excellent anesthesia based on ultrasound guidance that was independent of the evoked motor response.⁹⁵ In an AXB model, paresthesia was only 38% sensitive, and motor response was 75% sensitive even when ultrasound confirmed needle-to-nerve contact.¹⁶⁴ Yet, despite these differences in localizing the neural end point, ultrasound guidance has resulted in either similar¹⁶⁷ or marginally higher success rates as compared with PNS^{68,168} or perivascular techniques¹⁶⁹ (Table 3).

Ultrasound-Guided Brachial Plexus Blockade

Ultrasound-guided regional anesthesia may facilitate brachial plexus blockade in several ways, including enhanced visualization of the neural target and its surrounding structures, assessment of proper needle-tip position,³⁵ visualization of local anesthetic spread around the neural target,⁹⁶ identification of anomalous anatomy or pathology,^{175–179} optimizing nerve localization when PNS is problematic, such as in patients with amputations¹⁸⁰ or in patients with vascular anomalies,¹⁷⁸ and possibly enhanced block quality. Ultrasound may also improve resident learning of techniques pertinent to the safe and effective provision of brachial plexus anesthesia.^{181–185} With regard to the practice of commingling PNS and UGRA, 2 studies imply that combining the 2 techniques does not add value to ultrasound guidance alone. Block success was not improved when a motor response was present rather than unobtainable during needle placement for supraclavicular block.⁵² Similarly, block success was independent of the presence of a motor

TABLE 3. Randomized Double-Blind Studies of Ultrasound Guidance for Brachial Plexus Blockade

Author	Year	Approach	Design	Main Result
Williams et al ¹⁷⁰	2003	Supraclavicular	US+PNS vs PNS R, DB	Decreased block performance time with US
Marhofer et al ¹⁷¹	2004	Infralavicular; pediatric population	US vs PNS R, DB	Decreased sensory onset time and prolonged duration with US; less discomfort during block
Soeding et al ¹⁷²	2005	Interscalene and axillary	US vs surface landmarks, R, DB	Decreased sensory onset time and greater success with US; less paresthesias during block
Arcand et al ⁵²	2005	Infralavicular vs supraclavicular	US/PNS vs US/PNS R, DB	Greater radial nerve block failure in infralavicular group
Bigeleisen and Wilson ⁵⁹	2006	Infralavicular: medial vs lateral US approach	US vs US, R, open label	Medial approach faster performance time and more effective; less vascular puncture
Sites et al ¹⁶⁴	2006	Axillary	Transarterial vs US perivascular R, SB	Greater success in US group (less conversion to GA)
Dingemans et al ¹⁷³	2007	Infralavicular	US/PNS vs US alone R, open label	Faster performance time and greater block efficacy in US-alone group
Chan et al ¹⁶⁸	2007	Axillary	US/PNS vs US vs PNS R, DB	Greater block success in US/PNS and US group compared with PNS alone
Casati et al ¹⁶⁷	2007	Axillary	PNS vs US R, DB	No difference in block success; faster sensory onset and less procedure-related pain in US group
Kapral et al ⁶⁸	2008	Interscalene	PNS vs US R, SB	Greater block success in US group; better sensory, motor, and extent of blockade better in US group
Sauter et al ¹⁷⁴	2008	Infralavicular	PNS vs US R, DB	Equal success, performance time, onset, and patient comfort
Macaire et al ¹¹⁹	2008	Wrist	PNS vs US R, SB	Time to perform median and ulnar nerve blocks faster with US; total time (performance plus onset) and success were equivalent

Abbreviations: US, ultrasound; PNS, peripheral nerve stimulation; R, randomized; DB, double-blind; SB, single-blind.

response greater or less than 0.5 mA during ISB.¹⁸⁶ To date, no studies attest to enhanced safety with UGRA; indeed, recent case reports note that complications such as nerve injury and intravascular injection can still occur despite the use of ultrasound.^{187–189} Although clearly useful, there are also limitations to UGRA such as technical difficulty in nerve visualization from subcutaneous air or edema¹⁹⁰ and technical challenges in maintaining needle visualization.¹⁹¹

The feasibility of ultrasound guidance for brachial plexus blockade has been demonstrated for most of the major approaches to the plexus, including interscalene,⁶⁴ posterior cervical,^{77,78} supraclavicular,⁸¹ infraclavicular,¹⁷² and axillary¹⁰¹ blocks. Similar feasibility studies have been performed for selective blockade of the musculocutaneous,¹⁰⁸ median, ulnar,¹¹⁶ and radial¹¹⁷ nerves in the forearm.¹¹⁸ These feasibility studies have been followed by RCTs that compare various measures of anesthetic success with UGRA to success with PNS. The results of these trials are notable for their inconsistent findings, which are in part related to approach, operator experience, whether ultrasound machine setup is included in time comparisons, and end point definition (Table 3). For instance, performance time for supraclavicular¹⁷⁰ and infraclavicular¹⁷³ blocks is 4 to 5 mins faster when ultrasound guidance alone is compared with ultrasound guidance plus peripheral nerve stimulation. In most ultrasound studies, the onset of sensory and motor blockade of individual nerves is faster and duration is longer,^{68,167,171} which is likely due to the mass effect of local anesthetic applied precisely to nerves. Ultrasound guidance is associated with fewer needle passes and less patient discomfort during block performance.^{68,167} With regard to the most important clinical outcome of adequate surgical block, some^{68,168,169,192} but not all^{119,167,174} studies have shown improved block success rates with UGRA as compared with PNS (Table 3).

Continuous Perineural Catheter Blocks

Since publication of our previous review, scientific evidence has mounted supporting the usefulness of continuous perineural catheter techniques in upper extremity regional anesthesia. The strongest evidence from RCTs shows the ability of interscalene catheters to decrease resting and dynamic pain, opioid requirements and opioid-related side effects, and sleep disturbances after moderately to severely painful shoulder surgery.^{124,133} Similar benefit has been demonstrated for ambulatory continuous infusions via the interscalene^{126,133,193,194} and infraclavicular approaches.^{128,132,195,196} In experienced hands, these techniques are remarkably successful,¹⁹⁷ providing analgesia in 99% of patients⁶³ and improving rehabilitation and readiness for hospital discharge after total joint arthroplasty in most^{128,133,143} but not all studies.¹³¹ Considerably less information exists regarding the effectiveness and safety of continuous perineural infusions via the axillary,¹⁹⁸ supraclavicular,¹⁹⁹ intersternocleidomastoid,⁷⁹ and cervical paravertebral^{74,75,77,78} approaches.

Several technical issues are specific to continuous perineural catheter placement. Although catheter localization techniques include PNS,²⁰⁰ UGRA,^{193,201} and the use of stimulating catheters, the optimal method is unknown. Arguably, the limited data on stimulating versus nonstimulating brachial plexus catheters^{202,203} have taken on less importance as more catheters are placed under the direct ultrasonic visualization.²⁰⁴ Dosing strategies for continuous upper extremity blockade likely vary by approach to the brachial plexus.^{195,205} In general, the ability for patients to self-administer a bolus dose allows for a reduced basal infusion rate, decreased local anesthetic consumption, and

similar baseline analgesia but at the expense of an increase in breakthrough pain if the concomitant basal infusion is decreased.²⁰⁵ In the absence of extensive data, infusion settings for long-acting local anesthetics delivered to the brachial plexus include basal rate of 5 to 10 mL/h, bolus volume of 2 to 5 mL/h, and lockout duration of 20 to 60 mins. The relative roles of total drug dose versus local anesthetic concentration or volume in determining blockade quality are unknown.²⁰⁶ Various types of infusion pumps are available. Electronic pumps generally provide accurate and consistent flow during the entire course of infusion; elastomeric pumps tend to provide higher-than-expected basal rates initially and just before reservoir exhaustion; and spring-powered pumps tend to provide higher-than-expected infusion rates initially and lower-than-expected rates before reservoir exhaustion.^{207–209} Whether these inaccuracies and inconsistencies are relevant to daily clinical practice is unclear.

LOCAL ANESTHETIC AND ADJUVANT PHARMACOLOGY

Local Anesthetics

Few large controlled studies compare the various local anesthetics for brachial plexus blockade. Analysis of these studies is difficult by virtue of the many possible variations during a brachial plexus block procedure—which block technique is chosen, which adjuvant is added, pH of the injected solution, how duration is defined and measured, the surgical model, and individual patient characteristics. Despite these limitations, available literature provides insight into how local anesthetic agent selection, dose, concentration and volume, and physical modifications can affect onset, spread, quality, and duration of anesthesia.

Local Anesthetic Selection

Selecting a specific local anesthetic should be tailored to specific goals. In general, the intermediate-acting agents lidocaine and mepivacaine demonstrate faster onset and lower failure rates than bupivacaine or ropivacaine but at the expense of shorter analgesic duration.⁵⁰ However, 1 study of ISB found ~8-min faster onset and 2-times longer analgesic duration with plain 1% ropivacaine as compared with plain 2% mepivacaine.²¹⁰ Whether prolonged analgesia is desirable depends on how much the patient desires a numb extremity, the ability to protect the insensate arm from injury, and the surgeon's need to assess neurovascular function.

Contemporary studies mostly compare ropivacaine and levobupivacaine to racemic bupivacaine. Although 0.5% ropivacaine and 0.25% bupivacaine provide excellent analgesia,^{211,212} neither consistently provides surgical anesthesia.²¹³ For surgical anesthesia, sensory and motor block onset and duration were not different with plain 0.75% ropivacaine compared with plain 0.5% bupivacaine.^{69–71} Increasing plain ropivacaine concentrations up to 1% did not improve sensory and motor block success or analgesic duration as compared with plain 0.5% bupivacaine.^{214,215} Thus, 0.75% ropivacaine and 0.5% bupivacaine seem to be equivalent for brachial plexus anesthesia. Limited and somewhat conflicting studies have found levobupivacaine to have similar block characteristics as racemic bupivacaine²¹⁶ and equal-concentration ropivacaine.²¹⁷

Similar to single-shot applications, there is no evidence to support the superiority of one local anesthetic over another when used for continuous techniques. Direct comparison of

ropivacaine and bupivacaine is difficult because their precise equipotency is unknown. Equivalent analgesia has been reported using 0.125% bupivacaine and 0.125% ropivacaine for AXB,²¹⁸ or 0.2% ropivacaine and 0.125% levobupivacaine for ISB.²¹⁷ Preservation of motor function during continuous ISB seems to be minimally better with 0.2% ropivacaine than with 0.15% bupivacaine.²¹⁹

Dose, Concentration, and Volume

Whether increasing local anesthetic mass (mass = concentration \times volume) results in a higher success rate is controversial in clinical settings. Laboratory studies clearly indicate that neural blockade requires very little local anesthetic. A variety of animal models have shown that neural blockade can be successfully accomplished with extremely small amounts of local anesthetic. For example, neural blockade occurs with only 1.6% of the total injected volume of local anesthetic,²²⁰ with only 0.02% lidocaine concentration within the nerve,^{220,221} or with local anesthetic deposited along only 3 cm of nerve length.²²² Although these animal data represent an idealized state wherein local anesthetic is deposited directly on nerves, they suggest that anesthesiologists may well overdose local anesthetic in their clinical practice. Studies using ultrasonography vary in their findings on the ability to reduce local anesthetic volume without sacrificing block quality.⁸⁵

In a series of studies involving continuous AXB using 1% mepivacaine with epinephrine, Vester-Andersen et al^{223–227} systematically evaluated the role of volume, concentration, and dose on block efficacy. When dose was held constant, increasing volume from 20 to 40 to 80 mL had little effect on sensory blockade of most nerves,²²⁴ although motor block was superior at lower volumes, probably reflecting a concentration effect.²²⁵ When volume was held constant, sensory blockade was 70% to 100% successful in all nerve groups, regardless of increasing concentration (0.5% to 1% to 1.5%).²²⁵ Increasing the dose from 400 to 500 to 600 mg resulted in no difference in sensory or motor anesthesia.²²⁶ Ultimately, isolated changes in volume, concentration, or dose had minimal effect on sensory nerve blockade. Minor improvements in block quality were achievable only with the combination of increasing volume and drug mass. More recent studies corroborate these findings. Equivalent clinical axillary blockade occurs with 20-, 28-, or 38-mL volumes of 1% mepivacaine,²²⁸ whereas 5 or 20 mL 0.5% ropivacaine manifests equivalent analgesia after ultrasound-guided ISB.²²⁹ Similarly, 30, 40, or 60 mL of ropivacaine does not affect the onset of axillary sensory block.²³⁰ Purely analgesic block has been reported with as little as 10 mL of 0.25% bupivacaine or 0.5% ropivacaine.^{66,67} Increasing ropivacaine concentration does not significantly alter ISB characteristics.²¹⁴ In summary, onset, quality, and duration of brachial plexus local anesthetic blockade are not improved by arbitrarily increasing drug mass or its determinants, volume and concentration. Indeed, doing so may worsen local anesthetic systemic toxicity and neurotoxicity in the event of accident.

The onset and duration of brachial plexus block can also be linked to patient-related conditions. Block onset and duration are unaffected by altitude.²³¹ Anesthetic duration is not prolonged in patients with chronic renal failure.²³² The pharmacokinetic profile of levobupivacaine does not vary between patients with or without uremia,²³² whereas ropivacaine plasma concentrations 24 hrs after AXB are higher in patients with renal failure.²³³ Block onset is delayed in areas of local infection as compared with noninfected areas within the distribution of the same nerve.²³⁴

Local Anesthetic Mixtures

Mixtures of local anesthetics are intended to provide faster block onset than long-acting agents and to extend the duration typically seen with intermediate- or short-acting agents. Overall, mixtures provide few clinically significant advantages²³⁵ but instead result in a profile similar to a pure intermediate-acting agent.²³⁶ Furthermore, combined administration of local anesthetics produces epileptogenic effects that are additive.²³⁷ A more elegant approach to tailoring local anesthetic profile involves selective application of different local anesthetic agents or clonidine²³⁸ to individual nerves. By injecting lidocaine on the musculocutaneous and radial nerves, and bupivacaine on the median and ulnar nerves, one can achieve faster recovery from motor block but longer analgesic duration when compared with injecting a mixture of lidocaine and bupivacaine on all 4 nerves.²³⁹

Physical Manipulations

Certain physical manipulations of local anesthetic solutions have been evaluated as methods to improve brachial plexus block onset or spread. Alteration of local anesthetic temperature has contradictory effects. Injecting ice-cold lidocaine hastens block onset and increases duration but is painful.²⁴⁰ Warming local anesthetic to 37°C may²⁴¹ or may not quicken onset time.²⁴² Because local anesthetic blockade of sodium channels is use-dependent, exercising the arm after block placement significantly speeds up anesthesia onset but does not improve success or prolong duration.²⁴³ Conversely, the use of transcutaneous nerve stimulation to “exercise the arm” is of no benefit.²⁴⁴ Rapid injection of local anesthetic reduces anesthetic spread and increases failure rate.²⁴⁵ Firm digital pressure applied during the time of injection neither reduces the incidence of HDP^{66,246} nor improves block spread with the interscalene⁶⁶ or axillary approach.²²³ Finally, abduction of the arm to 0 degrees increases local anesthetic spread centrally with AXB but does not affect sensory blockade.²⁴⁷ Conversely, maintaining the arm in 90-degree abduction after AXB has been reported to improve onset and duration.²⁴⁸

Alkalinization of Local Anesthetics

Clinical studies are inconclusive regarding alkalinization of local anesthetics as a means of hastening block onset. The presence or absence of epinephrine is a central dividing point for analyzing this topic.^{249–251} Alkalinization seems most effective with commercially prepared epinephrine-containing local anesthetics, probably because these solutions are formulated at a lower pH and the relative effects of raising pH are greater than with plain local anesthetic solutions. However, when fresh epinephrine is added to plain lidocaine, onset times of brachial plexus anesthesia with alkalinization are similar to those seen without alkalinization.²⁵² The clinical significance of faster onset is questionable. For instance, adding sodium bicarbonate to mepivacaine with epinephrine significantly decreased sensory block onset time from 1.8 ± 0.2 to 1.0 ± 0.2 mins.²⁴⁹ Effects on other block characteristics are similarly unconvincing. For example, alkalinization does not improve sensory block success rate,^{251,252} nor does it affect plasma mepivacaine levels in the absence of epinephrine.²⁵³ There are no well-controlled clinical observations of the impact of alkalinization on peripheral nerve block intensity and duration in humans, but in rats, alkalinization of plain 1% lidocaine decreased block intensity by 25% and decreased block duration by more than 50%. Similar effects were not observed

with 1% lidocaine with epinephrine.²⁵⁴ In summary, clinical data do not support the alkalization of local anesthetics used for brachial plexus blockade.

Adjuvants

Significant prolongation of brachial plexus analgesia is ideally accomplished with placement of continuous catheters. For moderate prolongation of analgesia (<24 hrs), various adjuvant drugs can be admixed with local anesthetic. There are no ultralong-acting local anesthetics or slow-release formulations clinically available.²⁵⁵

Epinephrine

Epinephrine prolongs duration and intensity of most local anesthetics used for peripheral nerve block. For example, a 1:200,000 dilution (5 µg/mL) significantly increases the mean duration of lidocaine (264 with vs 186 mins without epinephrine). These effects are due to vasoconstriction, which prolongs the nerve's exposure to local anesthetic drug mass by limiting clearance.²⁵⁶ Other benefits of epinephrine include acting as a marker of intravascular injection²³⁵ and potentially limiting systemic local anesthetic toxicity by reducing time-to-peak concentration and peak plasma concentration, although the latter effect is not seen with ropivacaine.²⁵⁷ Adjunctive epinephrine is most effective with lipophobic local anesthetics such as mepivacaine or lidocaine, where it prolongs anesthetic duration in a dose-dependent manner up to a 1:200,000 dilution. Stronger concentrations are associated with hemodynamic side effects—increased heart rate and cardiac output and decreased peripheral vascular resistance.²⁵⁸ A 1:400,000 dilution (2.5 µg/mL) slightly decreases block duration as compared with 1:200,000 dilution (240 vs 264 mins, respectively)²⁵⁹ but is associated with minimal hemodynamic alteration and does not decrease nerve blood flow.²⁶⁰

Routine use of adjunctive epinephrine clearly prolongs brachial plexus block duration with little, if any, risk. However, on a theoretical basis with some supporting animal data, anesthesiologists may prefer to use weaker concentrations (1:400,000) or avoid epinephrine altogether in patients at risk for cardiac ischemia or potentially prone to nerve injury as a consequence of decreased blood flow secondary to chemotherapy, diabetes, or atherosclerotic disease.²⁶¹ Safety and efficacy data for admixing epinephrine in continuous perineural infusions are limited.²⁶⁰ For digital nerve blocks, there is no convincing evidence that epinephrine-containing local anesthetics are causally linked to digital ischemia.²⁶²

Clonidine

Clonidine is a useful adjuvant for brachial plexus blockade, particularly when admixed with intermediate-acting local anesthetics for AXB.²⁶³ Clinical evidence generally supports its use and has been extensively reviewed.²⁶³ Clonidine does not serve as an intravascular marker, nor does it significantly affect local anesthetic plasma levels. Prolongation of anesthesia and analgesia with brachial plexus clonidine is most likely peripherally mediated^{238,263} and, like its side effect profile, dose-dependent. Brachial plexus clonidine 150 µg delays the onset of pain by 2-fold when compared with systemic control,²⁶⁴ and 0.1 µg/kg prolongs analgesia by 50% compared with placebo (492 vs 260 mins). When added to mepivacaine, the minimum dose required to prolong analgesia is 0.1 µg/kg, whereas that needed to prolong anesthesia is 0.5 µg/kg. Side effects (hypotension, bradycardia, sedation) do not occur up to a dose of 1.5 µg/kg²⁶⁵ or a maximum dose of 150 µg or less.^{265–268}

The choice of local anesthetic affects the effectiveness of clonidine. Dose-dependent prolongation of clonidine admixed with mepivacaine or lidocaine is well established,²⁶⁹ but its ability to increase analgesic duration after brachial plexus blocks with long-acting local anesthetics is less pronounced.²⁶³ Clonidine accelerates block onset in areas of localized infection.²³⁴ Clonidine has no beneficial effects when used with continuous perineural infusions.^{126,270} Once pain occurs, the presence of clonidine does not alter its intensity.^{112,113,117} Clonidine does not affect tourniquet pain.²⁶⁶ Whether clonidine is better than, or adds value to, epinephrine-containing mixtures is uncertain,^{268,271} but 2 human studies that independently assessed the effects of epinephrine and clonidine using the same experimental model demonstrated greater lidocaine block prolongation with epinephrine.^{256,272}

Opioids

Peripheral opioid effects have been demonstrated with intra-articular injection and with wound infiltration, but the clinical relevance of peripheral opioid receptors is uncertain.^{273,274} This lack of basic science clarity extends to the clinical effects of adjunctive opioids used with brachial plexus blockade. Interpretation of clinical studies is difficult because many lack a control group from which to separate the possibility of systemic opioid effect. Indeed, as the quality of study improves, the evidence for a clinically significant peripheral opioid effect at the brachial plexus diminishes. Brachial plexus studies that include a systemic control group mostly fail to demonstrate compelling reasons to add opioids to anesthetizing solutions, most often finding no significant differences in the onset, duration, block quality, or pain scores.^{275–277} Systematic reviews of the role of opioids in peripheral nerve block conclude that their anesthetic and analgesic effects are not clinically relevant.²⁷⁸ If there is a role for additive opioid, it may be the addition of buprenorphine 0.3 mg as a means of prolonging analgesic duration.²⁷⁴

Other Adjuvant Drugs

A variety of other adjuvants for prolonging brachial plexus blockade have been reported but either are ineffective, are associated with side effects, or have unresolved issues related to neurotoxicity. Adenosine does not improve brachial plexus block quality.²⁷⁹ Tramadol, an analgesic with peripheral effects similar to local anesthetics and clonidine, moderately increases sensory block duration (approximately to the same degree as epinephrine or clonidine) in a dose-dependent manner up to 200 mg when compared with placebo or systemic control.^{37,280} The neurotoxicity of tramadol is unknown; however, it causes skin rash when administered subcutaneously.²⁸¹ Brachial plexus verapamil offers little advantage over epinephrine if expected surgical duration is less than 3.5 hrs.²⁷³ Neostigmine does not improve sensory or motor block qualities but is associated with a 30% incidence of gastrointestinal side effects.²⁸² Dexamethasone has been shown to prolong analgesia, based on an underpowered study without benefit of systemic control.²⁸³ There are theoretical concerns that dexamethasone may adversely affect peripheral nerve blood flow in diabetic patients and/or cause hyperglycemia.²⁸⁴ Ketamine does not improve ropivacaine blockade but is associated with side effects.²⁸⁵ Magnesium prolongs prilocaine AXB to the same extent as epinephrine²⁸⁶; its peripheral neurotoxicity profile has not been studied. Midazolam has been shown to prolong bupivacaine block by 2 hrs,²⁸⁷ but concerns have been raised regarding its neurotoxicity.²⁸⁸ Hyaluronidase does not hasten block onset,

reduce the incidence of failed block, or affect local anesthetic blood concentration, but it does shorten block duration.²⁸⁹ To date, there have been no studies evaluating nonsteroidal anti-inflammatory drugs as adjuvants for brachial plexus blockade.²⁹⁰

In summary, local anesthetic and adjuvant selection, as well as dosing, clearly affects brachial plexus block characteristics. Yet, despite our ability to modify local anesthetic solutions, it is unclear to what extent block spread and quality are more a function of technical intervention than pharmacological adjustment. Whereas no studies evaluate the pharmacological contributions of local anesthetic and adjuvant selection versus the technical issues of block selection and performance, anesthesiologists should be aware that both profoundly affect the success of brachial plexus anesthesia.

COMPLICATIONS

As with any medical procedure, brachial plexus anesthesia is associated with risks. Large outcome studies of major complications after brachial plexus block are limited.^{51,115,148,158,194,291–302} The incidence of various complications ranges from the extremely rare to the relatively common. For instance, a large study in France²⁹² included 21,278 peripheral nerve blocks, in which the incidence of cardiac arrest (0.01%), death (0.005%), seizures (0.08%), and radiculopathy (0.02%) was extremely small. In a follow-up study, the same group reported that the overall risk of a serious adverse event after peripheral nerve block was 0.04% (Table 4).²⁹¹ In its 1999 report, the American Society of Anesthesiologists (ASA) database of closed malpractice claims concerning anesthesia-related nerve injury (ARNI) noted that 28% involved the ulnar nerve (only 15% of these were associated with regional anesthesia) and 20% involved the brachial plexus (only 16% of which were directly attributable to regional anesthesia).²⁹⁵ Subsequent reports noted that 10% of brachial plexus injuries were for pneumothorax, whereas claims for death and brain damage were most commonly linked to local anesthetic systemic toxicity.^{298,299} Overall, the incidence of severe short- and long-term complications after ISB (catheter and single-shot techniques) is quite low (0.4%).²⁹³ Less serious complaints are common—for instance, 50% of patients undergoing AXB report at least 1 side effect such as soreness (40%), transient numbness (11%), or bruising (23%).²⁹⁶

Peripheral Nerve Injury

Perioperative nerve injury is a rare complication of regional anesthesia and can present as residual paresthesia, hypoesthesia, or rarely as permanent paresis.³⁰³ The overall

incidence of long-term nerve injury ranges between less than 0.02% and 0.4%, depending on the definition of injury and the length of follow-up.^{291–293,301} The timing of first presentation of neurological injury varies, with a substantial portion becoming apparent in the early postoperative period—ranging from 21% presenting immediately after surgery²⁹⁵ to 100% within 48 hrs of surgery.²⁹² Those deficits arising within the first 24 hrs most likely represent extraneural or intraneural hematoma, intraneural edema, or a lesion involving a sufficient number of axons to allow immediate diagnosis.^{114,302} Other subsets of ARNI present 1 to 28 days postoperatively.^{293,295} In the ASA Closed Claims Study²⁹⁵ database, median presentation was 3 days after surgery. Although most injuries are evident by 3 weeks, delayed symptoms can develop weeks after surgery.^{114,115,291–293,295,302} Such late presentation of neuropathy suggests an alternate mechanism, such as a tissue reaction or scar formation leading to neural fiber degeneration,³⁰³ or patient distraction by perioperative circumstances such as pain or immobility. Over time, the incidence of persistent ARNI decreases. In summary, evidence of neurological abnormality occurs within the first 24 hrs in up to 19% of patients,³⁰¹ but will decrease to 3% to 8% by 4 to 6 weeks^{293,301} and will be well less than 0.4% by 1 year.^{41,153,154,171}

Peripheral Nerve Injury and Brachial Plexus Blockade

Perioperative nerve injuries after upper extremity surgery may be the result of several contributing factors either unrelated or directly related to the regional anesthetic technique (Table 4). Unrelated risk factors include patient and surgical issues, with the latter being responsible for 89% of perioperative neurological complications in a report of 1614 blocks for upper extremity surgery.³⁰² Regional anesthetic factors that may contribute directly to ARNI include mechanical trauma, ischemic injury, or chemical injury. Whether patients with pre-existing clinical or subclinical injury that involves the brachial plexus are at increased risk for injury from a secondary insult during block placement (the “double-crush” phenomenon³⁰⁴) is a concern that is neither confirmed nor refuted by current literature.³⁰⁵ One large investigation did not link the risk of postoperative paresthesia to pre-existing paresthesia.³⁰² Similarly, the risk of new or exacerbated injury after ulnar nerve transposition did not vary with general or regional anesthesia, although injuries in the regional group were associated with ulnar nerve paresthesia during block placement.²⁹⁷ Brachial plexopathy has been reported after block placement in a patient who had received cisplatin³⁰⁶ and in another patient with multiple sclerosis.¹⁸⁸ Whether such cases reflect isolated instances of injury or are indicative of heightened risk is unknown; thus,

TABLE 4. Serious Complications Related to Upper Extremity Peripheral Nerve Blocks

Technique	Cardiac Arrest	Respiratory Failure	Death	Seizure	Permanent Neurological Injury
Interscalene block (N = 3459)	0	0	0	0	1 (2.9)
Supraclavicular block (N = 1899)	0	0	0	1 (5.3)	0
Axillary block (N = 11,024)	0	0	0	1 (0.9)	2 (1.8)
Midhumeral block (N = 7402)	0	0	0	1 (1.4)	1 (1.4)
Total peripheral nerve blocks* (N = 50,223)	1 (0.2)	2 (0.4)	1 (0.2)	6 (1.2)	12 (2.4)

Data presented are number and the estimated (n/10,000) where applicable.

*Data for *Total peripheral nerve blocks* also include lower extremity blocks that were reported in this study.

Modified from Auroy et al.²⁸⁴

practitioners are advised to weigh risk-to-benefit ratios and alternative anesthesia and analgesia techniques in patients with pre-existing neurological injury to the brachial plexus.³⁰⁵

Mechanical Trauma: The Role of Needle or Catheter Injury

Mechanical trauma, needle type, elicitation of paresthesias, and high injection pressure have all been investigated as contributors to peripheral nerve injury.^{114,115,301,302,307–309} Animal models have been used to examine needle type (long [14 degrees] vs short [45 degrees] bevel) and bevel configuration.^{307,310} Selander et al³¹⁰ examined the immediate (2 hrs) histological implications of needle trauma in isolated or in situ rabbit sciatic nerves. Neuronal injury occurred more frequently with long-beveled needles as compared with short-beveled ones. Whereas the overall frequency of nerve injury was less with short-beveled needles, injury severity was greater. Injury also varied in this study with bevel orientation, particularly with long-beveled needles, where transverse insertion caused more severe injury as compared with insertion parallel to nerve fibers. Rice and McMahon³⁰⁷ also noted that long-beveled needles in the parallel configuration produced less neuronal damage than transverse long- or short-beveled needles, both immediately after injury and at 7 days. Importantly, by 28 days, all injuries caused by long-beveled needles were resolving and overall nerve injury scores were significantly lower, whereas those induced by short-beveled needles continued to display evidence of severe injury (Fig. 16). They further demonstrated that neural repair may be accelerated and more organized with long-beveled injuries, making long-term consequences less concerning. The approach of Rice and McMahon³⁰⁷ of evaluating long-term histological and functional manifestations of injury may be more clinically relevant than the method of Selander et al.³¹⁰ Moreover, because multifasciculated rabbit nerve tends to slide away from needle tips, the model of Selander et al³¹⁰ may overstate the “protective effect” of short-beveled needles.

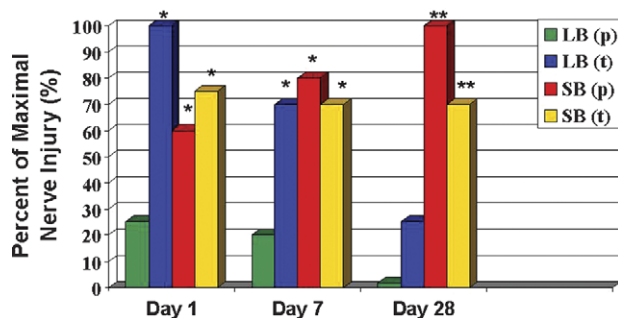


FIGURE 16. Percent of maximal rat sciatic nerve injury as a function of time, and needle bevel type and orientation. Nerve injury is determined by the cumulative score of 3 graded components: intraneuronal disruption (graded 0 to 5), axonal degeneration (graded yes/no), and disorganized fiber regeneration (graded yes/no). Nerve lesions induced by short-bevel needles are more severe and take longer to repair than those induced by long-bevel needles. Nerve injury induced by short-bevel needle was often associated with persisting signs of injury 28 days after the injury. LB(p) indicates long-bevel needle in parallel configuration to nerve fibers; LB(t), long-bevel needle in transverse configuration to nerve fibers; SB(p), short-bevel needle in parallel configuration to nerve fibers; SB(t), short-bevel needle in transverse configuration to nerve fibers. Reproduced by permission of Oxford University Press/*British Journal of Anaesthesia*.³⁰⁷

When fascicular impalement does occur, both studies agree that nerve injury is more severe with short-beveled needles. There are no RCTs to support or refute the ability of various needle types and bevel configurations to impale human nerves. Further clinical study is necessary before definitive recommendations can be made regarding the use of differently configured needles during peripheral nerve block. There is no evidence that larger-gauge needles used to place perineural catheters increase the risk of nerve injury.⁶³

Mechanical Trauma: The Role of Paresthesias

Whether the elicitation of a paresthesia represents direct needle trauma, thereby increasing the risk of nerve injury, is unknown. Clinical studies of paresthesia and ARNI have thus far been unable to definitively answer this question.^{114,115,148,301,309,310} Selander et al¹¹⁴ reported a higher incidence of ARNI in patients where a paresthesia was intentionally sought during AXB compared with those undergoing a perivascular technique (2.8% vs 0.8%, respectively; not significant). Because unintentional paresthesias were elicited and injected upon in patients within the perivascular group who then experienced ARNI, Winnie³¹¹ has argued that these results do in fact become statistically significant. Forty percent of patients within the perivascular group reported unintentional paresthesias, demonstrating the difficulty with standardization of technique, analysis of nerve injury, and, perhaps most importantly, the futility of completely avoiding a paresthesia when a needle is placed in proximity of a nerve. Auroy et al²⁹² noted that all cases of radiculopathy after peripheral nerve block were associated with either a paresthesia during needle insertion or pain on injection (paresthesia or discomfort coincident with local anesthetic injection) and that the neuropathy had the same topography as the associated paresthesia. In contrast to the above observations, the ASA Closed Claims Study²⁹⁵ found that only 31% of patients with persistent injury experienced paresthesia during needle placement or with local anesthetic injection, and a recent RCT noted no correlation between the location of a paresthesia or motor response and subsequent persistent paresthesia.³⁰⁰ A prospective investigation³⁰¹ using a variety of regional anesthetic techniques—transarterial, paresthesia, and nerve stimulator—failed to associate complication rates with technique, an observation that has been confirmed by others.^{148,300} Winchell and Wolfe³⁰⁹ reported a 0.36% incidence of ARNI, despite 98% of patients experiencing a paresthesia. Although this incidence is at the higher end of reported ARNI, resolution occurred in all patients within 7 months. These studies would seem to support Moore's³¹² contention that mechanical paresthesias are not, per se, an indication of nerve injury. In contrast, a recent study of ISB noted a 13-fold higher risk of developing neurological sequelae if a paresthesia was experienced during PNS-guided block placement.²⁹⁴ Finally, there is some evidence that neurological injury may vary by approach to the brachial plexus—the incidence of ARNI after PNS techniques was higher with ISBs than with AXBs (4% vs 1%, respectively).⁵¹ Although elicitation of paresthesia during regional techniques is not definitively linked to ARNI, pain on injection does seem to be more consistently linked to injury.^{305,313}

Does nonintra-neural injection of local anesthetic after a paresthesia, or supplemental injection after a failed block, increase the risk of nerve injury? Injury did not occur when local anesthetic was injected through an axillary catheter, although unintentional paresthesias were obtained during catheter placement in 39% of patients.³⁰⁸ Similarly, there was no ARNI in patients who experienced a paresthesia during transarterial AXB

when the needle was redirected before local anesthetic injection.³⁰¹ Yet, others have noted increased nerve injury associated with paresthesia despite redirection of the needle before injection.²⁹⁴ Because the intensity of paresthesias may be attenuated, probing near a partially anesthetized nerve for the purpose of supplementing incomplete anesthesia may theoretically increase the risk of neural injury. Two studies support this concern. Sixty-seven percent of patients with deficits lasting more than 1 year¹¹⁴ and 100% of patients with injury after transarterial AXB had received a supplemental injection.¹¹⁵ Techniques using multiple stimulations or paresthesia elicitation after partial injection of local anesthetic dose may also theoretically increase the risk of nerve injury, but this question has received limited study.⁵¹ There are no data to support or refute the safety of using ultrasound guidance during injection of supplemental local anesthetic around partially anesthetized nerves.

Mechanical Trauma: The Role of High Injection Pressures

Preliminary data from dogs have questioned if intrafascicular injection is consistently associated with higher injection pressures and if monitoring these pressures can predict and/or prevent nerve injury. Hadzic et al³¹⁴ have demonstrated that needles placed at the subperineurium (ie, into the nerve fascicle) required higher injection pressures 57% of the time as compared with subepineurium injections, which were always associated with low injection pressures. Dogs having intrafascicular injections that were concurrently associated with higher injection pressures developed severe, persistent motor deficits and histological pathology that was still present when the animals were euthanized a week later. Although these results are intriguing, there is no clinical correlation in humans. Furthermore, anesthesiologists are unable to discern injection pressures accurately based on "syringe feel."³¹⁵ An alternative method to prevent the development of high syringe pressure involves not compressing an air column within an injection syringe by more than 50% of its volume,³¹⁶ but this method is also limited by the absence of clinical data.

Ischemic Injury: The Role of Epinephrine and Neural Edema

The functional integrity of a peripheral nerve is highly dependent on its microcirculation,³¹⁷ which consists of an intrinsic supply of exchange vessels within the endoneurium and an extrinsic supply of larger, nonnutritive vessels (Fig. 5).³¹⁸ Extrinsic circulation is under adrenergic control and therefore highly responsive to epinephrine-containing solutions. For example, the topical application of plain 2% lidocaine reduces rat sciatic neural blood flow (NBF) by 39%, and adding epinephrine (5 µg/kg) results in an even greater (78%) reduction.³¹⁸ Although plain ropivacaine causes the greatest reduction in NBF (65%), this decrease is not worsened by the addition of epinephrine; nor are histopathologic changes apparent 48 hrs after administration.³¹⁹ Whether such dramatic experimental reduction in NBF is relevant in humans is unclear. Epinephrine is likely safe when applied to nerve fascicles with intact tissue barriers but may accentuate injury in the event of barrier disruption, such as may occur after an intraneural injection³²⁰ or in individuals with chemotherapy-related neurotoxicity, diabetic neuropathies,³²¹ or atherosclerosis. Vast human experience suggests that even these risks are decidedly remote, but there are no human RCTs that specifically evaluate adjuvant epinephrine as a factor contributing to ARNI.²⁶¹

Ischemic nerve injury may also occur after the intrafascicular injection of local anesthetic.^{320,322} Intrafascicular injection

can result in compressive nerve sheath pressures that exceed 600 mm Hg for up to 15 mins. Elevated pressure interferes with endoneurial microcirculation³²² and may alter the permeability of the blood-nerve barrier, resulting in axonal degeneration and axonal dystrophy. Subsequent fibroblast proliferation at the site of injury contributes to late-occurring changes in perineural thickness and endoneurial fibrosis.³²³ These changes may result in delayed tissue reaction or scar formation, accounting for symptoms that develop days or even weeks after peripheral nerve blockade.^{114,291,292,295,302}

Chemical Injury: The Role of Local Anesthetic Neurotoxicity

Clinical experience suggests that local anesthetic drugs are overwhelmingly safe when administered correctly and in the recommended concentrations. However, when inappropriately high concentrations, prolonged exposure times (eg, continuous infusions or epinephrine), or intraneuronal injections are encountered, severe degenerative changes may occur leading to neurological sequelae.^{154,320} The persistent neurotoxic effects of local anesthetics are concentration-dependent and seem to parallel anesthetic potency.³²⁴ Acute-phase (48 hrs) histopathologic and functional effects completely resolve 10 to 14 days later—observations that apply to histological changes³²⁵ as well as changes to compound action potentials.³²³ These changes happen with both long- and short-acting agents, with and without epinephrine. Continuous catheter techniques raise concern about potential neurotoxicity from repeated perineural injection of local anesthetic. Kroin et al³²⁶ examined the neurotoxic effects of perisciatric injection of equipotent lidocaine doses repeated 3 times a day for 3 days in rats. Severe neurotoxicity occurred with 4% lidocaine only when rapid dilution of the drug was prohibited, but lidocaine 1% and 2% was innocuous regardless of dilutional factors. Similarly, Kyatta et al³²⁷ noted myelin sheath injury after repeated injection of 0.5% bupivacaine around rat sciatic nerve over 3 days but no nerve damage after a 3-hr infusion of bupivacaine. Limited clinical evidence has not found continuous perineural local anesthetic infusion to increase the risk of nerve injury over that seen with single-shot techniques.²⁹³

Regional anesthesia-induced nerve injury may require a combined mechanical and chemical insult (Fig. 17).^{154,320,325} Selander et al³²⁰ demonstrated that topical application of bupivacaine, with or without epinephrine, was innocuous in rabbits, whereas intraneural injection resulted in severe neural injury. Saline and plain 0.5% bupivacaine resulted in a similar degree of nerve injury, suggesting that injury was not from the injected test solution but rather was the result of injection trauma alone. However, higher concentrations of bupivacaine (1%) or the addition of epinephrine (1:200,000) to 0.5% bupivacaine resulted in significantly more severe axonal injury than saline or 0.5% bupivacaine alone. In contrast, Rice et al³⁰⁷ failed to document significant injury after saline injection alone. Although intraneuronal injection of 0.2% or 0.75% plain ropivacaine does not have a deleterious effect on rat sciatic nerve motor function,³²⁹ this single study does not establish ropivacaine as being less neurotoxic than other local anesthetics used clinically.

THE ROLE OF LOCALIZATION TECHNIQUE

Peripheral Nerve Stimulation

The use of electrical stimulation to locate peripheral nerves was introduced in 1962.³³⁰ Several advantages have been claimed with this technique, including a higher success

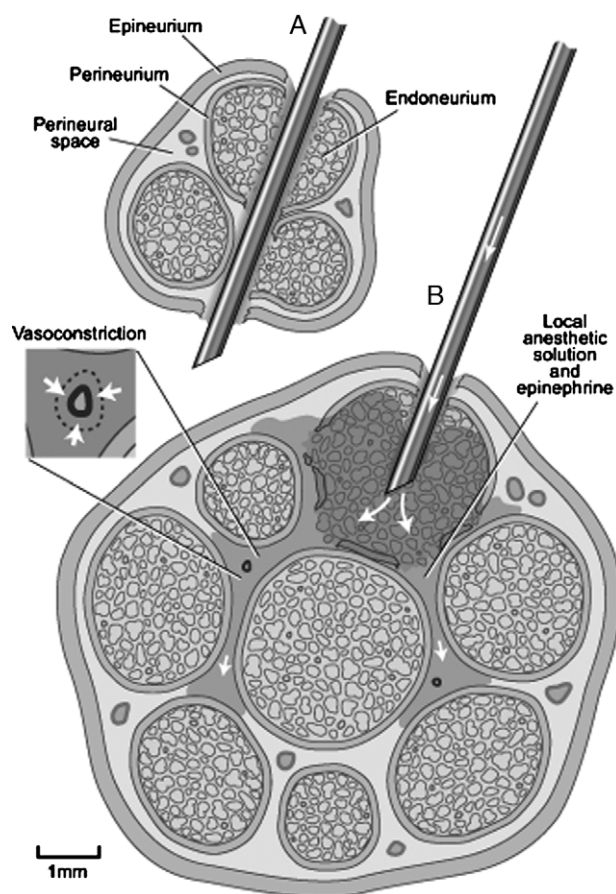


FIGURE 17. Mechanisms of peripheral nerve injury. Direct needle trauma can rarely lacerate a nerve (A) or, more typically, injure the perineurium (B) and thereby expose the axons to potential local anesthetic neurotoxicity (shaded area). Vasoconstrictors may worsen injury by reducing local anesthetic clearance (inset). Illustration by Gary J. Nelson. Reproduced with permission from Neal and Rathmell. *Complications in Regional Anesthesia and Pain Medicine* (Elsevier Saunders).³²⁸

rate, the avoidance of vascular injury, and the avoidance of paresthesias and associated neurological injury.^{105,157,311,331} There is evidence that PNS can reduce the frequency of unintended paresthesia to ~15%^{51,332} and facilitate readiness for surgery as compared with paresthesia techniques.¹⁶⁰ However, there are no human RCTs that clearly support the assertion that PNS improves patient safety. Neurological complication rates associated with PNS range from 0%^{157,158} to more than 10%,^{294,300} but within each of these investigations, there were no statistically significant differences between techniques (nerve stimulator, paresthesia, transarterial). Some advocates of the PNS approach argue that it provides exact needle localization without actually contacting nerve tissue. However, investigations have examined the relationship between a subjective paresthesia and an objective motor response elicited by a PNS in patients undergoing interscalene or axillary blockade.^{152,153} Nearly 25% of patients initially reporting paresthesia required a current of more than 0.5 mA to manifest a motor response, suggesting an inconsistency of elicited motor responses despite the needle presumably being near a nerve. Concerns were therefore raised that awareness of a paresthesia subsequent to needle advancement could be compromised in

sedated or anesthetized patients, thus potentially subjecting them to unrecognized intraneural injection.^{153,155,160,305,313} Such concerns are further validated by reports of nerve injury after low-current (<0.5 mA) electrical stimulation²⁹² and intramedullary injection during the course of PNS-assisted ISB in anesthetized patients.³³³ These clinical data are further strengthened by recent animal studies in which stimulating needles were inserted into the nerves under direct vision, yet the electrical current required to achieve a motor response could exceed 1 mA.¹⁶⁶ Therefore, the assertion that nerve stimulation allows clinicians to approach neural structures without the risk of mechanical trauma does not seem to be valid. In part because of the above concerns, the ASRA Practice Advisory on Neurologic Complications of Regional Anesthesia and Pain Medicine suggests that brachial plexus blockade, particularly the interscalene approach, not be undertaken routinely in anesthetized patients.^{305,313}

Ultrasound Guidance

Similar to peripheral nerve stimulation, UGRA holds the potential for reducing ARNI. Using ultrasound guidance, it is possible to observe a block needle penetrating a peripheral nerve in both animals^{166,334} and humans.¹⁴⁷ Studies in animals¹⁶⁶ and humans^{163,164} also demonstrate the variability of motor response to nerve stimulation even when the needle is observed by ultrasound to be within or touching the nerve. These findings suggest that ultrasound guidance might facilitate avoidance of unwanted needle-to-nerve contact. However, no clinical studies exist to confirm or refute these potential advantages of ultrasound guidance,^{187,305} and nerve injury has occurred despite its use.¹⁸⁸

Diagnosis and Evaluation of Neurological Complications

Patient, surgical, and anesthetic risk factors may all contribute to perioperative nerve injury (Table 5). Although most neurological complications completely resolve within several days or weeks, significant injuries necessitate neurological consultation to locate the lesion, document the degree of injury,

TABLE 5. Risk Factors Contributing to Perioperative Nerve Injury

Categories	Perioperative Risk Factors
Patient risk factors	Pre-existing neurological disorders Male sex Increasing age Extremes of body habitus
Surgical risk factors	Pre-existing diabetes mellitus Surgical trauma or stretch Tourniquet ischemia Vascular compromise Perioperative inflammation Postoperative infection Hematoma Cast compression or irritation Patient positioning
Anesthetic risk factors	Needle or catheter-induced mechanical trauma Ischemic injury (vasoconstrictors) Perineural edema Local anesthetic toxicity

and coordinate further evaluation and rehabilitation. Although some recommend waiting until evidence of denervation has appeared before performing neurophysiological testing (typically 2–3 weeks after injury), a baseline study (including evaluation of the contralateral extremity) is often helpful in ruling out underlying pathology or a pre-existing condition.³³⁵ Furthermore, persistent symptoms may occur secondary to other readily treatable disease processes such as carpal tunnel syndrome or complex regional pain syndrome.²⁹³ When faced with a complete or progressive postoperative nerve deficit, anesthesiologists are urged to seek immediate neurosurgical consultation for evaluation of possible reversible causes of injury. Conversely, improving or stable injuries can be observed or require less urgent neurological consultation.^{305,335}

In summary, ARNI remains a rare but poorly understood complication of brachial plexus anesthesia that is likely multifactorial in nature (Fig. 17). Our lack of knowledge is underscored by the absence of human RCTs of sufficient statistical power to confidently link risk to outcome. Furthermore, anesthesiologists seem to both underestimate the true risk of nerve injury and then fail to fully disclose this risk to their patients.^{336,337} Most admonitions for eschewing ARNI—such as short-beveled needles, avoidance of paresthesia, injection pressure monitoring, or the use of PNS or ultrasound for nerve localization—have no clinical evidence upon which to base their acceptance. Nevertheless, certain risk factors for ARNI emerge from analysis of accumulated evidence. These include damage to axonal protective coverings perpetrated by intraperineurium injection, the likely worsening of injury by local anesthetics or epinephrine when the structural integrity of the fascicle has been compromised, and the potentially increased risk of performing brachial plexus blockade, especially via the interscalene approach, in anesthetized or heavily sedated patients.^{305,313}

Hemidiaphragmatic Paresis

The proximity of the phrenic nerve and its originating cervical nerve roots (C3–C5) to the brachial plexus¹² frequently leads to unintended local anesthetic blockade and resultant diaphragmatic dysfunction (Fig. 18). The frequency and clinical relevance of this side effect vary with block site but should be carefully considered when providing above the clavicle techniques in patients with underlying pulmonary disease. The incidence of HDP is 100% after ISB.^{338–342} Some patients will report mild dyspnea or altered respiratory sensations and may experience 25% to 32% reduction in spirometric measures of pulmonary function.³⁴⁰ The development of HDP and pulmonary function changes is not altered by the application of digital pressure during block injection, reducing local anesthetic volume to 20 mL using PNS techniques,^{339,341} or both.²⁴⁶ Single injection of 10 mL 0.25% bupivacaine has been shown to attenuate HDP and accompanying spirometric changes as compared with 0.5% bupivacaine.³³⁸ A recent study has shown that decreasing the volume of local anesthetic from 20 to 5 mL using an ultrasound-guided technique can decrease both the incidence and severity of HDP.²²⁹ Conversely, a preliminary report that used 10 mL local anesthetic administered via ultrasound guidance was unable to demonstrate a difference in HDP compared with that observed with 20 mL.³⁴³ Abnormal diaphragmatic function persists in 50% of patients after 24 hrs of dilute bupivacaine continuous infusion.³⁴⁴ Ropivacaine's purported ability to preserve motor function was not protective in one study,³⁴⁵ whereas another³⁴⁶ showed minimally better spirometric values after nonequipotent concentrations of ropivacaine and bupivacaine. Acute respiratory failure and lobar

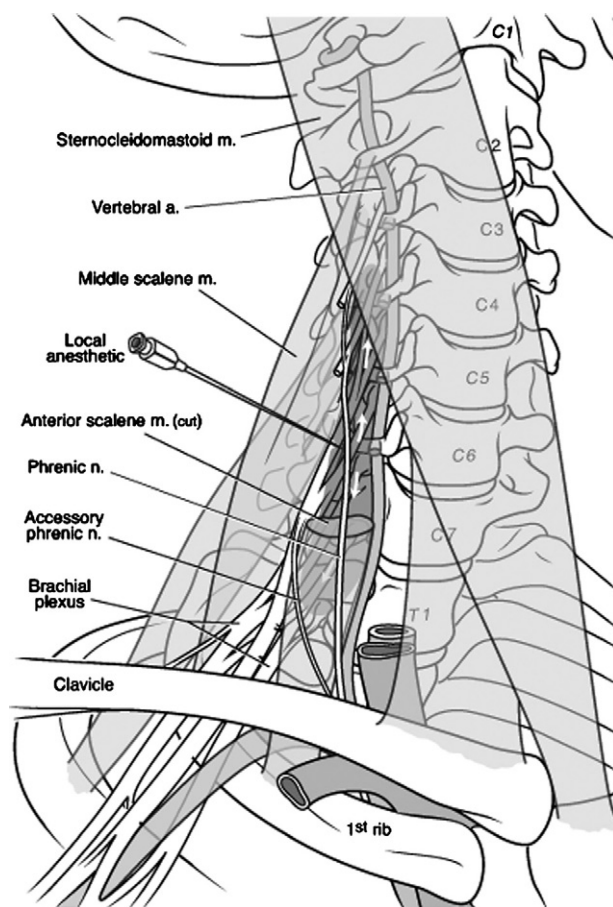


FIGURE 18. Mechanisms of phrenic nerve blockade.

Hemidiaphragmatic paresis occurs as a consequence of phrenic nerve blockade during brachial plexus blocks. The phrenic nerve can be blocked as local anesthetic moves cephalad to the C3–C4 nerve roots (shading), as the phrenic nerve passes nearby the C5 nerve root, or as the phrenic nerve courses along the anterior scalene muscle. Illustration by Gary J. Nelson. Reproduced with permission from Neal and Rathmell. *Complications in Regional Anesthesia and Pain Medicine* (Elsevier Saunders).³²⁸

collapse have been reported after continuous interscalene infusion of local anesthetic in patients with marginal pulmonary function.^{347,348} Of note, a continuous catheter study in healthy patients using 0.2% ropivacaine showed diaphragmatic and pulmonary functions similar to a patient-controlled intravenous opioid group.³⁴⁹

Supraclavicular block has a lower incidence of HDP as compared with the interscalene approach (50%; 95% confidence interval, 14%–86%) and is not associated with respiratory symptoms or change in pulmonary function.³⁵⁰ The presence or absence of pulmonary function changes after supraclavicular block may reflect the degree of diaphragmatic paresis.³⁵¹ In contrast to the more medially placed vertical infraclavicular approach, the lateral infraclavicular approaches, that is, coracoid³⁵² and Raj,³⁵³ are not associated with pulmonary function changes.^{90,354} Because HDP occurs in all patients administered ISB with local anesthetic 20 mL or greater and happens unpredictably after supraclavicular and medial ICBs, none of these approaches are recommended in patients unable to tolerate a 30% reduction in pulmonary function. Although ultrasound guidance may²²⁹ or may not³⁴³ reduce the incidence of HDP,

neither does ultrasound guidance eliminate it, nor have the relatively less severe changes in spirometric values been clinically linked to less respiratory compromise in at-risk patients.

Although HDP is usually transient, rare cases of permanent phrenic nerve paresis have been reported after ISB and may reflect trauma to the phrenic nerve or an unknown etiology.^{355–357} There are anecdotal reports of phrenic nerve injury after the intersternocleidomastoid approach. Persistent hiccups, presumably a reflection of phrenic nerve irritation, have been reported after ISB.³⁵⁸

Pneumothorax

Pneumothorax is a serious complication associated with supraclavicular approaches, including the ISMB. It has also been reported following interscalene,²⁹³ coracoid and vertical infraclavicular,^{359,360} and suprascapular blocks. The historical incidence of pneumothorax after supraclavicular block was 0.5% to 6.1%, which reflected experience with classic supraclavicular approaches, wherein the anesthetizing needle was guided toward the apical pleura.³⁶¹ The plumb-bob and subclavian perivascular approaches were designed in part to lessen the risk of pneumothorax.⁸⁰ The risk of pneumothorax in tall, thin patients may be further reduced by initially directing the needle 45 degrees cephalad during the supine plumb-bob technique, rather than directly toward the floor; this magnetic resonance imaging finding has not been confirmed clinically.³⁶² Experience with more than 3000 nonobese¹⁵⁶ and obese³⁶³ patients suggests that the risk of pneumothorax is 0.1% or less (upper limit of 95% confidence interval) using the subclavian perivascular approach. Because the pleura and first rib are often easy to visualize, UGRA may theoretically reduce the risk of pneumothorax. Although existing studies are too small to confirm these purported advantages,¹⁷⁰ ultrasound-guided approaches do replace the traditional cephalad-to-caudad³⁶⁴ or anterior-to-posterior⁸⁰ needle approach with either lateral-to-medial⁸¹ or medial-to-lateral³⁶⁵ approach whose trajectories are less in-line with the lung.

Patients who develop pneumothorax are not likely to report symptoms for 6 to 12 hrs (in the absence of positive pressure ventilation). This implies futility of early chest radiographs and raises concerns about performing these blocks on outpatients with problematic medical follow-up. Many patients report only mild symptoms, primarily pleuritic chest discomfort.³⁶⁶ A chest radiograph taken during full exhalation confirms the diagnosis of pneumothorax.

Local Anesthetics—Unintended Destinations

Intravascular Injection

The proximity of the brachial plexus to major vascular structures invites intravascular injection of local anesthetic. This complication occurred in 0.2% of patients receiving transarterial AXB in one study, despite test dosing and aspiration.¹¹⁵ The incidence of systemic signs of local anesthetic injection through perineural catheters is also 0.2%.⁶³ Even with ultrasound guidance, placement of perineural catheters results in vascular puncture in 0% to 11% of patients, with the range most likely reflecting differences in anatomic approach and needle/catheter characteristics.^{75,132,195,196,270,347} The use of ultrasound per se does not eliminate intravascular injection of local anesthetic.^{189,367} Intra-arterial injection can be dramatic during interscalene or supraclavicular block, because local anesthetic injected directly into the vertebral or carotid artery, or retrograde flow via the subclavian artery, proceeds directly to the brain. The estimated convulsant doses after unintended carotid or vertebral artery injection are lidocaine 14.4 mg and bupivacaine 3.6 mg; symptomatic toxicity has been reported at similar doses.³⁶⁸ Intravenous injection may allow larger volumes to be injected before toxicity. The tissue absorption rate of local anesthetic does not vary as a function of brachial plexus block approach.³⁶⁹ Gradual absorption of local anesthetic from tissue depots results in slowly rising local anesthetic concentrations, which cause systemic toxicity less frequently as compared with relatively lower concentrations that rise quickly as a result of intravascular injection.³⁷⁰ Local anesthetic concentrations should peak 10 to 30 mins after single injection or up to 1 hr if epinephrine has been added. Up to 48 hrs of 9-mL/hr infusion of 0.2% ropivacaine results in plasma levels well below those associated with central nervous system toxicity,³⁷¹ as does 5 days of continuous bupivacaine infusion.³⁷²

What constitutes the maximum safe recommended local anesthetic dose for brachial plexus anesthesia is controversial and poorly grounded in evidence. Peak arterial plasma levels of local anesthetic do not correlate with body surface area or patient weight.^{373,374} Despite manufacturers' recommended dosages, there are multiple published reports of significantly higher doses delivered to the brachial plexus without adverse sequelae, although the safety of this practice is not well studied.^{67,100} Importantly, local anesthetic toxicity may become problematic in patients with compromised pharmacokinetics secondary to congestive heart failure, advanced age, or hepatic failure or those undergoing continuous techniques.³⁷⁴ Total doses in these patients should be reduced, but to what extent is poorly defined.

The incidence of seizure after peripheral nerve block is 5 times more likely as compared with epidural injection.²⁹² This scenario is best avoided by meticulous test dosing,³⁷⁵ aspiration, and fractionated dosing with continuous observation for signs and symptoms of local anesthetic toxicity, understanding that these maneuvers are not totally reliable.¹¹⁵ No data attest to the value of using ultrasound to reduce the frequency of intravascular injection, but there are reports of intravascular injection despite its use.^{189,367} The seizure rate per 1000 patients varies according to the brachial plexus approach selected—1.2 to 1.3 for axillary (equally likely to occur with a transarterial, PNS, or midhumeral technique¹⁵⁸), 3 to 7.6 for interscalene,²⁹⁴ 1 to 7.9 for supraclavicular,^{363,376} and up to 10 for vertical infraclavicular approaches.³⁷⁷ Continuous axillary catheters are associated with seizures in up to 8 per 1000 blocks.³⁴⁷ Compared with seizures, the risk of cardiovascular collapse after unintentional intravascular injection is less certain. Animal studies suggest a margin of safety afforded by lidocaine over longer-acting agents (safety ratio of 1:2:9 representing bupivacaine–levobupivacaine/ropivacaine–lidocaine, respectively). The safety profile of levobupivacaine as compared with ropivacaine is less clear,^{378,379} but cardiovascular collapse does occur with bupivacaine and ropivacaine.^{380,381} Most importantly, anesthesiologists should understand that the risk of intravascular injection with subsequent seizure is very high with brachial plexus anesthesia, perhaps exceeded only by caudal anesthesia.^{292,376} Should cardiac systemic toxicity occur with ropivacaine or bupivacaine, advanced cardiac life support protocols should be instituted immediately and consideration given to early administration of lipid emulsion.[†]

Subarachnoid or Epidural Injection

Local anesthetics intended for the brachial plexus may spread to the neuraxis. Single-shot and continuous interscalene

†The ASRA Practice Advisory on Local Anesthetic Toxicity is expected to be published in *Regional Anesthesia and Pain Medicine* in 2009.

and posterior paravertebral blocks have been linked to unintended subarachnoid and cervical or thoracic epidural blocks.^{75,382,383} Spinally mediated bradycardia, hypotension, apnea, and/or cardiac arrest can follow and may require timely and definitive resuscitation, including epinephrine.³⁸² Needle or catheter entry into the subarachnoid space can occur directly, or uncommonly via the dural cuff or injection into the nerve or ganglion (Fig. 19). These complications are best avoided by using shorter needles, directing the needle slightly caudad to avoid the intervertebral foramen, by slow/fractionated injection, and perhaps by lower volumes. Cadaver studies emphasize the nearness of the central neuraxis to an ISB needle. The minimum distances from skin to the C6 foramen and vertebral column are 23 and 35 mm, respectively.^{383,384} Imaging studies suggest that the risk of needle entry into the spinal canal, using the Winnie approach, can be reduced by using a more proximal entry point and a more steeply angled needle (>50 degrees caudad).³⁸⁴ There are no clinical studies to verify these image-based findings, although neuraxial injection has not been linked to the modified lateral⁶³ or middle³⁸⁵ interscalene approach.

Cervical Sympathetic Chain

Excessive local anesthetic spread can also affect the cervical sympathetic chain (Fig. 20), causing the patient to manifest Horner syndrome. This side effect occurs with interscalene,³⁸⁶ vertical infraclavicular, and especially supraclavicular (20%–90%)^{82,382} and cervical paravertebral (40%) blocks.⁷⁵ Although lower injectate volume may logically decrease the likelihood of Horner syndrome, this association is unproven.³³⁹ Cervical sympathetic chain anesthesia has been associated with continuous blocks via the lateral interscalene approach.⁶³ Other than educating patients regarding the temporary nature of this phenomenon, there is generally no harm from its occurrence. Rarely, continuous techniques have been linked to prolonged³⁸⁷ and delayed Horner syndrome.³⁸⁸

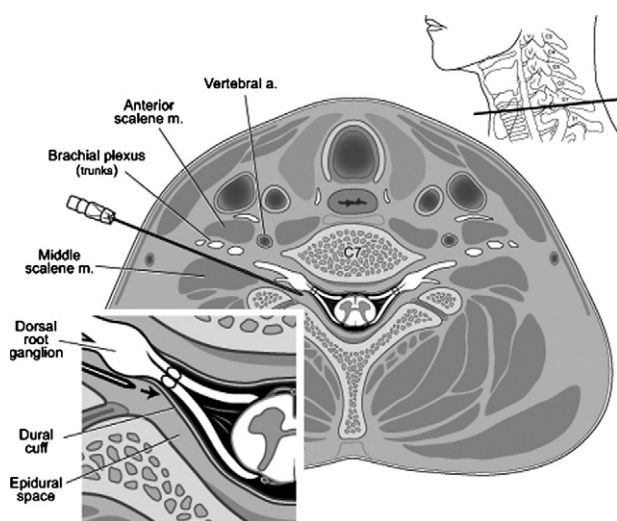


FIGURE 19. Mechanisms of unintended neuraxial block during interscalene brachial plexus anesthesia. The spinal canal and its contents are within 35 mm of the skin in most patients and can be accessed by unintentionally deep needle placement. Needles can also enter long dural root cuffs, thereby accessing cerebrospinal fluid (inset). Illustration by Gary J. Nelson. Reproduced with permission from Neal and Rathmell. *Complications in Regional Anesthesia and Pain Medicine* (Elsevier Saunders).³²⁸

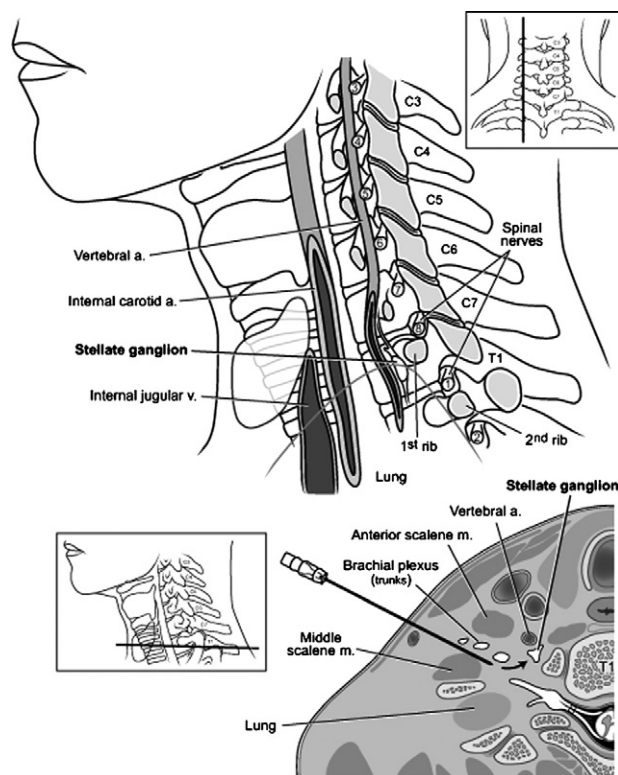


FIGURE 20. Mechanisms of cervical sympathetic trunk anesthesia. The stellate ganglia is quite close to the brachial plexus. Diffusion of local anesthetic from properly placed needles near the brachial plexus can unintentionally anesthetize the stellate ganglia (arrow) and cause Horner syndrome. Illustration by Gary J. Nelson. Reproduced with permission from Neal and Rathmell. *Complications in Regional Anesthesia and Pain Medicine* (Elsevier Saunders).³²⁸

Recurrent Laryngeal Nerve

Hoarseness may transpire after ISB³⁸⁶ and after 1.3% of supraclavicular blocks⁸² but has not been reported with the infraclavicular approaches. Continuous techniques have been associated with this side effect in 0.8% to 0.9% of interscalene^{63,347} and 10% of cervical paravertebral approaches.⁷⁵ Hoarseness presumably occurs as a consequence of excessive local anesthetic spread to the recurrent laryngeal nerve (Fig. 21), although its etiology is not fully understood. Hoarseness may occur in conjunction with Horner syndrome^{75,386} and is primarily a nuisance side effect that is best treated with patient reassurance.

Infection

Serious infections associated with continuous or single-shot brachial plexus blocks are extremely rare. Whereas catheter tip colonization is frequent (29%), 2 large series reported inflammation in 0.8% to 3% of patients and abscess formation in only a single diabetic patient.^{63,347} A third series of 3491 patients noted inflammation in 4.2%, infection in 2.4%, and infection requiring incision and drainage in 0.8% of patients, despite the routine use of hair covering, face mask, and sterile gown.³⁸⁹ Risk factors for catheter-related inflammation include intensive care unit admission, catheter duration of more than 48 hrs, male sex, the absence of prophylactic antibiotic at the time of insertion, and operator experience.^{347,389} The 2004

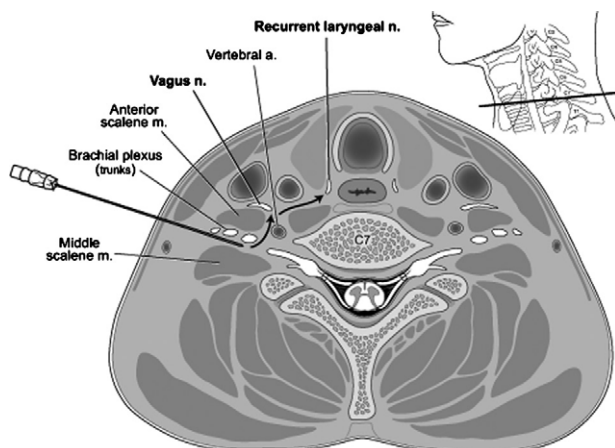


FIGURE 21. Mechanisms of recurrent laryngeal nerve anesthesia. The recurrent laryngeal nerve and vagus nerve can be unintentionally anesthetized during the course of brachial plexus regional anesthesia. Local anesthetic diffuses or tracks through tissue planes (arrows) and causes hoarseness during the blockade's duration. Illustration by Gary J. Nelson. Reproduced with permission from Neal and Rathmell. *Complications in Regional Anesthesia and Pain Medicine* (Elsevier Saunders).³²⁸

ASRA Practice Advisory on Infectious Complications of Regional Anesthesia and Pain Medicine³⁹⁰ suggests methods for reducing the risk of infection, including aseptic technique³⁹¹ and carefully weighing the risk-to-benefit ratio of placing catheters in febrile, infected,³⁹² or immunocompromised patients.³⁹³

Hypotensive/Bradycardic Events

Severe, sudden hypotensive and/or bradycardic events (HBE) have been reported in 13% to 24% of awake sitting patients undergoing shoulder arthroscopy with interscalene brachial plexus anesthesia.^{394,395} Possible etiologies of HBE included β_1 -agonist effects of exogenous epinephrine and activation of the Bezold-Jarisch reflex.³⁹⁶ This reflex occurs when the combination of decreased venous return and heightened sympathetic tone leads to forceful contraction of a near-empty left ventricle, with consequent parasympathetically mediated arterial vasodilation and bradycardia (Fig. 22). The incidence of HBE is decreased when prophylactic metoprolol (but not glycopyrrolate) is administered after block placement in 2.5-mg increments to an end point of either heart rate of less than 60 beats/min or maximal dose of 10 mg.³⁹⁶ Clinically, HBE is unpredictable, typically occurring 61 ± 18 mins after block placement and often heralded by light-headedness or nausea.³⁹⁴ The vast majority of these events are reported in minimally to moderately sedated patients. Whether the incidence is different in patients under general anesthesia or a combined technique is unknown.

Vascular Injury

Vascular complications are rare but potentially devastating events that are reported with varying frequencies during upper extremity regional anesthesia. Unlike the risks of anticoagulation and neuraxial blockade, the risk for brachial plexus vascular injury in anticoagulated patients is less well defined. The ASRA Guidelines on Anticoagulation and Regional Anesthesia³⁹⁷ suggest that performing brachial plexus blocks in patients who are mildly to moderately anticoagulated is not contraindicated, provided risk-to-benefit is considered. Increased caution

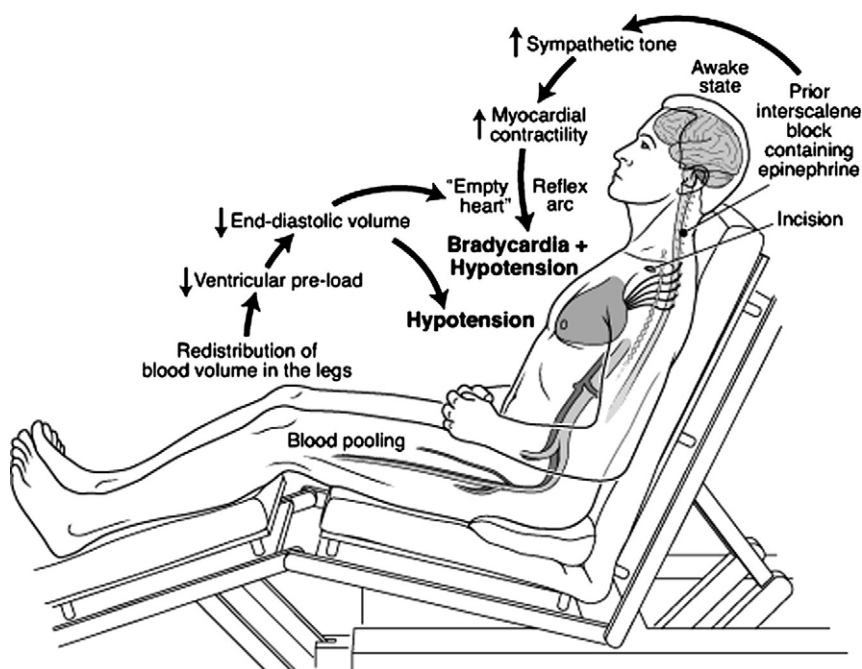


FIGURE 22. Mechanisms of hypotension/bradycardia. Patients who receive interscalene brachial plexus block, are sedated, and are placed in the beach-chair position may develop hypotension and bradycardia during their anesthetic course. The proposed mechanism for this phenomenon is a relative preload deficit from the sitting position, combined with a hypercontractile ventricle, which occurs as a consequence of exogenous and endogenous epinephrine. The vigorously contracting "empty" heart causes reflex bradycardia and hypotension. Illustration by Gary J. Nelson. Reproduced with permission from Neal and Rathmell. *Complications in Regional Anesthesia and Pain Medicine* (Elsevier Saunders).³²⁸

is prudent in those blocks where an expanding hematoma could compress the airway or be difficult to access.

Transient vascular insufficiency is a reported complication of brachial plexus blocks, occurring in up to 1% of patients.¹¹⁵ Vasospasm may follow arterial puncture or be a consequence of local anesthetic-induced vasoconstriction.^{398,399} Treatment includes intra-arterial lidocaine (being mindful of total local anesthetic dose to avoid high plasma levels), topical warming, or nitroglycerin paste.⁴⁰⁰ The risk of hematoma immediately after brachial plexus techniques is small (0.001%–0.02%),^{45,43,224,259} although the incidence may increase at 1-month follow-up.¹⁵⁸ Hematomas occur at a slightly higher rate with continuous catheters as compared with single-shot techniques.⁶³ Although most are inconsequential, hematomas have^{401,402} or have not³⁰¹ been associated with postoperative paresthesias or transient nerve injury. Pseudoaneurysm formation is another rare complication of brachial plexus blocks.^{403,404} Pressure-induced neural ischemia with subsequent neurological impairment may occur because of the close proximity of neurovascular structures within the axilla. Risk factors include the extent of the injury (number of needle punctures), impaired vascular elasticity, diabetes mellitus, hypertension, and anticoagulation.⁴⁰³ Axillary artery dissection can result from intramural injection of local anesthetic.⁴⁰⁵ In summary, vascular complications are rare after brachial plexus blockade but must be considered in patients with postoperative neurological impairment. Early recognition and prompt surgical intervention are critical to avoid long-lasting neurological sequelae.

Muscle Injury

Local anesthetics can cause myonecrosis,³²⁷ with bupivacaine producing the most intense effect. Because damage is dose related, continuous local anesthetic administration may worsen injury. Epinephrine and steroid also intensify this effect, which produces immediate and complete destruction of adult myocytes. Local anesthetic myotoxicity is dependent on a nonspecific increase in sarcoplasmic reticulum permeability to calcium. Immature myocytes are spared because they lack an internal calcium reservoir; consequently, new muscle regenerates over 3 to 4 weeks.⁴⁰⁶ Short-term continuous perineural infusion models in animals confirm myotoxicity with bupivacaine and, to a lesser extent, ropivacaine.^{407,408}

Perineural Catheter Complications

Large prospective studies involving more than 5500 patients suggest that the incidence of complications with continuous catheter techniques is very low and perhaps even lower than incidences reported with single-shot techniques.^{63,347,389} Several complications are unique to continuous catheter techniques. For instance, the most common complication is unintentional dislodgement, which can occur in 0% to 30% of patients. However, the combination of liquid adhesive, subcutaneous tunneling of the catheter, and securing the catheter-hub connection with tape or specifically designed devices can reduce catheter dislodgement to less than 5% over 6 to 9 days.¹⁴² Catheters may also knot and shear. Although knotting is distinctly uncommon, any catheter that is difficult to remove or causes pain or paresthesia during initial traction should prompt discontinuation of removal efforts and evaluation for minimally invasive or surgical removal.^{409,410}

Tourniquet Effects

Occlusive tourniquets are applied to the upper extremity to improve the surgical field. Ischemic nerve or muscle damage is unlikely in the noncompressed area if flow is re-established

within 6 hrs, but damage may occur under the cuff within 2 to 4 hrs.⁴¹¹ Tourniquet pressures in excess of 400 mm Hg have been linked to nerve injury.⁵¹ Up to 40 mins is necessary to return to normal metabolic status after 3 hrs of tourniquet inflation.⁴¹² Tourniquets produce pain by a complex mechanism, most likely involving neural ischemia.⁴¹³ Reperfusion almost immediately relieves tourniquet pain, although a transient second phase (not usually seen with regional techniques) may ensue.⁴¹⁴

PERIOPERATIVE ISSUES

Informed Consent and Documentation

Informed consent and its proper documentation are essential elements in the practice of medicine,^{415,416} yet evidence suggests that regional anesthesiologists both inaccurately estimate the risk of major complications and frequently fail to discuss these risks with their patients.^{336,337} Both medical⁴¹⁷ and legal⁴¹⁵ experts decry this practice. Accurate documentation of brachial plexus blockade has become more complicated as a result of perineural catheter placement, ultrasound guidance, and reimbursement and regulatory requirements for documentation. Consequently, forms to facilitate documentation have been developed.⁴¹⁸

Avoiding Wrong-Side Block

The Joint Commission on Accreditation of Healthcare Organizations has focused attention on eliminating wrong-sided surgeries and other procedures such as regional blocks. A method to prevent wrong-sided block incorporates a “pause” just before placing the block needle at the injection site. Elements of a pause include (1) confirming the patient's identity, (2) confirming the intended procedure, (3) verifying agreement of the anesthesiologist and patient regarding the correct side of the intended procedure, and (4) visually confirming that the proper surgical site has been clearly marked on the patient's skin.^{419,420} Nonetheless, wrong-side blocks have been reported despite the methods created to prevent them.^{421,422}

Limb Protection and Discharge Criteria

Studies have addressed the issue of limb protection after block placement, particularly when continuous techniques are used.^{142,423,424} It is generally safe to discharge patients, including children,⁴²⁵ with partial sensory block or continuous infusions.^{267,268,270,271} Patients with residual or continuous upper extremity sensory and/or motor block should be properly fitted with a sling or similar protective device. Instructions should include a warning to protect the insensate limb from pressure or thermal injury and advice as to when to expect sensory block resolution. Especially with continuous ambulatory techniques, patients should be provided with detailed written instructions and physician contact information. Indeed, when this is provided, 97% of patients report feeling safe and are accepting ambulatory analgesic techniques.^{193,424} As an alternative to prolonged motor blockade, the midhumeral approach allows for selectively anesthetizing individual nerves to achieve faster motor block resolution while maintaining prolonged analgesia of nerves within the surgical site.²³⁹ Selective application of clonidine also prolongs analgesia while limiting motor block.²³⁸

FUTURE RESEARCH DIRECTIONS

On the occasion of our 2002 review of brachial plexus anesthesia, we suggested future directions for research to fill gaps in existing knowledge. It is heartening that the ensuing

6 years have indeed made great, and at times amazing, strides toward these goals. New imaging modalities, particularly UGRA, have resulted in an exponential proliferation of scientific literature that is rapidly moving from pure description of techniques to meaningful comparison of ultrasound guidance to existing standards such as PNS. An exciting spin-off of this work is increased understanding of needle-to-nerve proximity. In 2002, few would have guessed, much less admitted, that block needles are frequently touching or within nerves (when viewed by ultrasound), yet this needle-to-nerve proximity is not invariably associated with the expected paresthesia or motor response. So important has ultrasound become that *Regional Anesthesia and Pain Medicine* created a new section in the journal devoted to UGRA and its related topics.⁴²⁶ The intervening years have also witnessed an unprecedented proliferation of adequately powered studies that compare meaningful outcomes of upper extremity blockade to fast-track general anesthesia and do so based on relevant definitions of success (ie, surgical block of all major terminal nerves within 30 mins) and in germane populations of patients (ie, those undergoing moderately to severely painful surgeries). In this same vein, continuous perineural catheter techniques have been subjected to increasingly sophisticated evaluation in terms of their ability to improve immediate outcomes such as analgesia and reduction of opioid-related side effects, and investigators have also begun to assess the ability of perineural techniques to affect longer-term outcomes such as hospital discharge or improved rehabilitation. We previously noted the need for further understanding of 2 serious complications of brachial plexus anesthesia—peripheral nerve injury and systemic local anesthetic toxicity. Although ultrasound guidance, improvements in peripheral nerve stimulation technology,⁴²⁷ and injection pressure monitoring have yet to be proven clinically effective in reducing the frequency of nerve injury, it is reasonable to speculate that these new technologies will improve our understanding of basic pathophysiology of nerve injury, which should in turn improve outcomes. Contemporaneously, advances in lipid emulsion rescue of systemic local anesthetic toxicity⁴²⁸ hold promise for improving our ability to treat this potentially fatal complication. Indeed, ASRA will publish the proceedings of its 2008 Practice Advisory on Local Anesthetic Toxicity in 2009. Finally, we noted the challenges of training physicians in old techniques and new technologies. Recent studies have introduced or validated new tools used to assess resident learning,^{429,430} provided insight into the education of regional anesthesia fellows,² and suggested guidelines for regional anesthesia fellowship training.⁴³¹ Moreover, ASRA and the European Society of Regional Anaesthesia and Pain Therapy have published their suggested curriculum for learning ultrasound, which addresses both resident and postgraduate physician learners.⁴³²

Despite great progress, challenges remain and acquisition of knowledge serves only to expand the list of questions. The largest gap in contemporary knowledge of upper extremity regional anesthesia is the need for further high-quality data, including well-designed RCTs, concerning the effectiveness of ultrasound guidance for improving block quality and efficiency as compared with existing nerve localization techniques.⁴³³ Enhanced safety with UGRA remains unproven; indeed, recent case reports of complications demonstrate that the technique will not completely eliminate serious complications. Yet, more than any other recent technology in regional anesthesiology, UGRA has the potential to improve efficiency and safety—the challenge is to prove it so. Two other barriers to the universal adoption of UGRA as the standard of care for nerve localization are the high cost of equipment and the issue of anesthesiologist training.^{72,432} With regard to continuous peri-

neural catheter techniques, will their proven short-term benefits be extended to show improvement in health-related quality of life? Which patients most benefit from perineural infusions? What are the best delivery, dosing strategy, and drug combinations? Finally, regional anesthesiology, just as the entire specialty of anesthesiology,⁴³⁴ is challenged by the need to train a sufficient number of academicians and researchers to continue to improve and advance our specialty into the future.⁴³⁵

REFERENCES

- Hall RJ. Hydrochlorate of cocaine. *N Y Med J*. 1884;40:643–646.
- Neal JM, Kopacz DJ, Liguori GA, Beckman JD, Hargett MJ. The training and careers of regional anesthesia fellows—1983–2002. *Reg Anesth Pain Med*. 2005;30:226–232.
- Neal JM, Hebl JR, Gerancher JC, Hogan QH. Brachial plexus anesthesia: essentials of our current understanding. *Reg Anesth Pain Med*. 2002;27:402–428.
- Gray's Anatomy. *The Anatomical Basis of Clinical Practice*. 39th ed. Standing S. Edinburgh: Elsevier Churchill Livingstone; 2005.
- Martinoli C, Bianchi S, Santacroce E, Pugliese F, Graif M, Derchi LE. Brachial plexus sonography: a technique for assessing root level. *AJR*. 2002;179:699–702.
- Kerr AT. The brachial plexus of nerves in man, the variations in its formation and branches. *Am J Anat*. 1918;23:285–395.
- McCann PD, Bindelglass DF. The brachial plexus: clinical anatomy. *Orthop Rev*. 1991;20:413–419.
- Harry WG, Bennet JDC, Guha SC. Scalene muscles and the brachial plexus: anatomical variations and their clinical significance. *Clin Anat*. 1997;10:250–252.
- Natsis K, Totlis T, Tsikaras P, Anastasopoulos N, Skandalakis P, Koeble J. Variations of the course of the upper trunk of the brachial plexus and their clinical significance for the thoracic outlet syndrome: a study on 93 cadavers. *Am Surg*. 2006;72:188–192.
- Moayeri N, Bigeleisen PE, Groe GJ. Quantitative architecture of the brachial plexus and surrounding compartments, and their possible significance for plexus blocks. *Anesthesiology*. 2008;108:299–304.
- Winnie AP, Tay C-H, Patel KP, Ramamurthy S, Durrani Z. Pharmacokinetics of local anesthetics during plexus blocks. *Anesth Analg*. 1977;56:852–861.
- Kessler J, Schafhalter-Zoppoth I, Gray AT. An ultrasound study of the phrenic nerve in the posterior cervical triangle: implications for the interscalene brachial plexus block. *Reg Anesth Pain Med*. 2008;33:545–550.
- Thompson GE, Brown DL. The common nerve blocks. In: Nunn JF, Utting JE, Brown BR, eds. *General Anaesthesia*. 5th ed. London: Butterworths; 1989:1068–1069.
- Borene SC, Edwards JN, Boezaart AP. At the cords, the pinkie towards: interpreting infraclavicular motor responses to neurostimulation. *Reg Anesth Pain Med*. 2004;29:125–129.
- Brown DL. *Atlas of Regional Anesthesia*. 3rd ed. Philadelphia: Elsevier Saunders; 2006.
- Sauter AR, Smith H-J, Stubhaug A, Dodgson MS, Klaastad O. Use of magnetic resonance imaging to define the anatomical location closest to all three cords of the infraclavicular brachial plexus. *Anesth Analg*. 2006;103:1574–1576.
- Partridge BL, Katz J, Benirschke K. Functional anatomy of the brachial plexus sheath: implications for anesthesia. *Anesthesiology*. 1987;66:743–747.
- Retzl G, Kapral S, Greher M, Mauritz W. Ultrasonographic findings in the axillary part of the brachial plexus. *Anesth Analg*. 2001;92:1271–1275.

19. Cornish PB. The sheath of the brachial plexus? A matter of life and death [letter]. *Reg Anesth Pain Med.* 2008;33:385–386.
20. Franco CD. Reply to Dr. Cornish. *Reg Anesth Pain Med.* 2008;33:386.
21. Thompson GE, Rorie DK. Functional anatomy of the brachial plexus sheaths. *Anesthesiology.* 1983;59:117–122.
22. de Jong RH. Axillary block of the brachial plexus. *Anesthesiology.* 1961;22:215–225.
23. Winnie AP, Collins VJ. The subclavian perivascular approach of brachial plexus anesthesia. *Anesthesiology.* 1964;25:353–363.
24. Cornish PB, Greenfield LJ. Brachial plexus anatomy. *Reg Anesth.* 1997;22:106–107.
25. Cornish PB, Leaper C. The sheath of the brachial plexus. Fact or fiction? *Anesthesiology.* 2006;105:563–565.
26. Cornish PB, Leaper CJ, Hahn JL. The “axillary tunnel”: an anatomic reappraisal of the limits and dynamics of spread during brachial plexus blockade. *Anesth Analg.* 2007;104:1288–1291.
27. Klaastad O, Smedby O, Thompson GE, Tillung T, Hol PK, Rotnes JS, et al. Distribution of local anesthetic in axillary brachial plexus block: a clinical and magnetic resonance imaging study. *Anesthesiology.* 2002;96:1315–1324.
28. Franco CD, Rahman A, Voronov G, Kerns JM, Beck RJ, Buckenmaier CC. Gross anatomy of the brachial plexus sheath in human cadavers. *Reg Anesth Pain Med.* 2008;33:64–69.
29. Hogan QH, Erickson SJ. MR imaging of the stellate ganglion: normal appearance. *Am J Roentgen.* 1992;158:655–659.
30. Handoll HHG, Koscielniak-Nielsen ZJ. Single, double or multiple injection techniques for axillary brachial plexus block for hand, wrist or forearm surgery *Cochrane Database Syst Rev.* 2006; Art. no.: CD003842;DOI: 10.1002/14651858.CD14003842.pub14651852.
31. Koscielniak-Nielsen ZJ. Multiple injections in axillary block: where and how many? *Reg Anesth Pain Med.* 2006;31:192–195.
32. Brand L, Papper EM. A comparison of supraclavicular and axillary techniques for brachial plexus blocks. *Anesthesiology.* 1961;22:226–229.
33. Thompson AM, Newman RJ, Semple JC. Brachial plexus anaesthesia for upper limb surgery: a review of eight years' experience. *J Hand Surg Br.* 1988;13:195–198.
34. Moorthy SS, Schmidt SI, Dierdorf SF, Rosenfeld SH, Anagnostou JM. A supraclavicular lateral paravascular approach for brachial plexus regional anesthesia. *Anesth Analg.* 1991;72:241–244.
35. Kapral S, Krafft P, Eibenberger K, Fitzgerald R, Gosch M, Weinstabl C. Ultrasound-guided supraclavicular approach for regional anesthesia of the brachial plexus. *Anesth Analg.* 1994;78:507–513.
36. Fleck JW, Moorthy SS, Daniel J, Dierdorf SF. Brachial plexus block: a comparison of the supraclavicular lateral paravascular and axillary approaches. *Reg Anesth.* 1994;19:14–17.
37. Kapral S, Gollmann G, Walzl B, Likar R, Sladen RN, Weinstabl C, et al. Tramadol added to mepivacaine prolongs the duration of an axillary brachial plexus blockade. *Anesth Analg.* 1999;88:853–856.
38. Koscielniak-Nielsen ZJ, Rotboll Nielsen P, Risby Mortensen C. A comparison of coracoid and axillary approaches to the brachial plexus. *Acta Anaesthesiol Scand.* 2000;44:274–279.
39. Sia S, Lepri A, Campolo MC, Fiaschi R. Four-injection brachial plexus block using peripheral nerve stimulator: a comparison between axillary and humeral approaches. *Anesth Analg.* 2002;95:1075–1079.
40. Fleischmann E, Marhofer P, Greher M, Walzl B, Sitzwohl C, Kapral S. Brachial plexus anesthesia in children: lateral infraclavicular vs. axillary approach. *Paediatr Anaesth.* 2003;13:103–108.
41. Deleuze A, Gentilli ME, Marret E, Lamonerie L, Bonnet F. A comparison of a single-stimulation lateral infraclavicular plexus block with a triple-stimulation axillary block. *Reg Anesth Pain Med.* 2003;28:89–94.
42. March X, Pardina B, Torres-Bahi S, Navarro M, del Mar Garcia M, Villalonga A. A comparison of a triple-injection axillary brachial plexus block with the humeral approach. *Reg Anesth Pain Med.* 2003;28:504–508.
43. Minville V, Amathieu R, Luc N, Gris C, Fourcade O, Samii K, et al. Infraclavicular brachial plexus block versus humeral approach: comparison of anesthetic time and efficacy. *Anesth Analg.* 2005;101:1198–1201.
44. Ertug Z, Yegin A, Ertem S, Sahin N, Hadimioglu N, Dosemeci L, et al. Comparison of two different techniques for brachial plexus block: infraclavicular versus axillary technique. *Acta Anaesthesiol Scand.* 2005;49:1035–1039.
45. Heid FM, Jage J, Guth M, Bauwe N, Brambrink AM. Efficacy of vertical infraclavicular plexus block vs. modified axillary plexus block: a prospective, randomized, observer-blinded study. *Acta Anaesthesiol Scand.* 2005;49:677–682.
46. Koscielniak-Nielsen ZJ, Rasmussen H, Hesselbjerg L, Nielsen TP, Gurkan Y. Infraclavicular block causes less discomfort than axillary block in ambulatory patients. *Acta Anaesthesiol Scand.* 2005;49:1030–1034.
47. Minville V, Fourcade O, Idabouk L, Classen J, Chassery C, Nguyen L, et al. Infraclavicular brachial plexus block versus humeral block in trauma patients: a comparison of patient comfort. *Anesth Analg.* 2006;102:912–915.
48. Niemi TT, Salmela L, Aromaa U, Poyhia R, Rosenberg P. Single-injection brachial plexus anesthesia for arteriovenous fistula surgery of the forearm: a comparison of infraclavicular coracoid and axillary approach. *Reg Anesth Pain Med.* 2007;32:55–59.
49. Riegler FX. Brachial plexus block with the nerve stimulator: motor response characteristics at three sites. *Reg Anesth.* 1992;17:295–299.
50. Schroeder LE, Horlocker TT, Schroeder DR. The efficacy of axillary block for surgical procedures about the elbow. *Anesth Analg.* 1996;83:747–751.
51. Fanelli G, Casati A, Garancini P, Torri G. Nerve stimulator and multiple injection technique for upper and lower limb blockade: failure rate, patient acceptance, and neurologic complications. Study Group on Regional Anesthesia. *Anesth Analg.* 1999;88:847–852.
52. Arcand G, Williams SR, Chouinard P, Boudreault D, Harris P, Ruel M, et al. Ultrasound-guided infraclavicular block versus supraclavicular block. *Anesth Analg.* 2005;101:886–890.
53. DeJose MB, Banus E, Navarro EM, Serrano S, Perello M, Mabrok M. Ultrasound-guided supraclavicular vs infraclavicular brachial plexus block in children. *Paediatr Anaesth.* 2008;9:838–844.
54. Bouaziz H, Narchi P, Mercier FJ, Labaille T, Zerrouk N, Girod J, et al. Comparison between conventional axillary block and a new approach at the midhumeral level. *Anesth Analg.* 1997;84:1058–1062.
55. Dalens B, Vanneville G, Tanguy A. A new parascapular approach to the brachial plexus in children: comparison with the supraclavicular approach. *Anesth Analg.* 1987;66:1264–1271.
56. Pippa P, Aito S, Cominelli E, Doni L, Rabassini M, Marinelli C, et al. Brachial plexus block using the transcoracobraclial approach. *Eur J Anaesthesiol.* 1992;9:235–239.
57. Pippa P. Brachial plexus block using a new subclavian perivascular technique: the proximal cranial needle approach. *Eur J Anaesthesiol.* 2000;17:120–125.
58. Koscielniak-Nielsen Z, Rasmussen H, Nielsen PT. Patients' perception of pain during axillary and humeral blocks using multiple nerve stimulation. *Reg Anesth Pain Med.* 2004;29:328–332.

59. Bigeleisen P, Wilson M. A comparison of two techniques for ultrasound guided infraclavicular block. *Br J Anaesth*. 2006;96:502–507.
60. Rettig HC, Gielen MJM, Jack NTM, Boersma E, Klein J. A comparison of the lateral and posterior approach for brachial plexus block. *Reg Anesth Pain Med*. 2006;1:119–126.
61. Fuzier R, Fourcade O, Pianezza A, Gilbert ML, Bounes V, Olivier M. A comparison between double-injection axillary brachial plexus block and midhumeral block for emergency upper limb surgery. *Anesth Analg*. 2006;102:1856–1858.
62. Winnie AP, Ramamurthy S, Durrani Z. Interscalene cervical plexus block: a single injection technic. *Anesth Analg*. 1975;54:370–375.
63. Borgeat A, Dullenkopf A, Ekotodramis G, Nagy L. Evaluation of the lateral modified approach for continuous interscalene block after shoulder surgery. *Anesthesiology*. 2003;99:436–442.
64. Chan VW. Applying ultrasound imaging to interscalene brachial plexus block. *Reg Anesth Pain Med*. 2003;28:340–343.
65. Vester-Andersen T, Christiannsen C, Hansen A, Sorensen M, Meisler C. Interscalene brachial plexus block: area of analgesia, complications and blood concentrations of local anesthetics. *Acta Anaesthesiol Scand*. 1981;25:81–84.
66. Urmey WF, Grossi P, Sharrock NE, Stanton J, Gloeggler PJ. Digital pressure during interscalene block is clinically ineffective in preventing anesthetic spread to the cervical plexus. *Anesth Analg*. 1996;83:366–370.
67. Lanz E, Theiss D, Jankovic D. The extent of blockade following various techniques of brachial plexus block. *Anesth Analg*. 1983;62:55–58.
68. Kapral S, Greher M, Huber G, Willschke H, Kettner S, Kdolsky R, et al. Ultrasonographic guidance improves the success rate of interscalene brachial plexus blockade. *Reg Anesth Pain Med*. 2008;33:253–258.
69. Roch JJ, Sharrock NE, Neudachin L. Interscalene brachial plexus block for shoulder surgery: a proximal paresthesia is effective. *Anesth Analg*. 1992;75:386–388.
70. Silverstein WB, Saiyed MU, Brown AR. Interscalene block with a nerve stimulator: a deltoid motor response is a satisfactory endpoint for successful block. *Reg Anesth Pain Med*. 2000;25:356–359.
71. Bollini CA, Urmey WF, Vascello L, Cacheiro F. Relationship between evoked motor response and sensory paresthesia in interscalene brachial plexus block. *Reg Anesth Pain Med*. 2003;28:384–388.
72. Salinas FV, Neal JM. A tale of two needle passes [editorial]. *Reg Anesth Pain Med*. 2008;33:195–198.
73. Pippa P, Cominelli E, Marinelli C, Aito S. Brachial plexus block using the posterior approach. *Eur J Anaesth*. 1990;7:411–420.
74. Boezaart A, Koorn R, Rosenquist RW. Paravertebral approach to the brachial plexus: an anatomic improvement in technique. *Reg Anesth Pain Med*. 2003;28:241–244.
75. Boezaart AP, de Beer JF, Nell ML. Early experience with continuous cervical paravertebral block using a stimulating catheter. *Reg Anesth Pain Med*. 2003;28:406–413.
76. Sandefo I, Iohom G, Van Elstraete A, Lebrun T, Polin B. Clinical efficacy of the brachial plexus block via the posterior approach. *Reg Anesth Pain Med*. 2005;30:238–242.
77. Antonakakis JG, Sites BD, Shiffren J. Ultrasound-guided posterior approach for the placement of a continuous interscalene catheter. *Reg Anesth Pain Med*. 2009;34:64–68.
78. Mariano ER, Loland VJ, Ilfeld BM. Interscalene perineural catheter placement using an ultrasound-guided posterior approach. *Reg Anesth Pain Med*. 2009;34:60–63.
79. Pham-Dang C, Gunst JP, Gouin F, Poirier P, Touchais S, Meunier JF, et al. A novel supraclavicular approach to brachial plexus block. *Anesth Analg*. 1997;85:111–116.
80. Brown DL, Cahill DR, Bridenbaugh LD. Supraclavicular nerve block: anatomic analysis of a method to prevent pneumothorax. *Anesth Analg*. 1993;76:530–534.
81. Chan VW, Perlas A, Rawson R, Odukoya O. Ultrasound-guided supraclavicular brachial plexus block. *Anesth Analg*. 2003;97:1514–1517.
82. Hickey R, Garland TA, Ramamurthy S. Subclavian perivascular block: influence of location of paresthesia. *Anesth Analg*. 1989;68:767–771.
83. Smith BE. Distribution of evoked paraesthesias and effectiveness of brachial plexus block. *Anaesthesia*. 1986;41:1112–1115.
84. Beach ML, Sites BD, Gallagher JD. Use of a nerve stimulator does not improve the efficacy of ultrasound-guided supraclavicular nerve blocks. *J Clin Anesth*. 2006;18:580–584.
85. Duggan E, El Beheiry H, Perlas A, Lupu M, Nuica A, Chan VW, et al. Minimum effective volume of local anesthetic for ultrasound-guided supraclavicular brachial plexus block. *Reg Anesth Pain Med*. 2009. In press.
86. Kapral S, Jandrasits O, Schabernig C, Likar R, Reddy B, Mayer N, et al. Lateral infraclavicular plexus block vs. axillary block for hand and forearm surgery. *Acta Anaesthesiol Scand*. 1999;43:1047–1052.
87. Salazar CH, Espinosa W. Infraclavicular brachial plexus block: variation in approach and results in 360 cases. *Reg Anesth Pain Med*. 1999;24:411–416.
88. Wilson JL, Brown DL, Wong GY. Infraclavicular brachial plexus block: parasagittal anatomy important to the coracoid technique. *Anesth Analg*. 1998;87:870–873.
89. Koscielniak-Nielsen ZJ, Rasmussen H, Hesselbjerg L, Gurkan Y, Belhage B. Clinical evaluation of the lateral sagittal infraclavicular block developed by MRI studies. *Reg Anesth Pain Med*. 2005;30:329–334.
90. Rettig HC, Gielen MJM, Boersma E, Klein J, Groen GJ. Vertical infraclavicular block of the brachial plexus: effects on hemidiaphragmatic movement and ventilatory function. *Reg Anesth Pain Med*. 2005;30:529–535.
91. Rodriguez J, Barcena M, Alvarez J. Restricted infraclavicular distribution of the local anesthetic solution after infraclavicular brachial plexus block. *Reg Anesth Pain Med*. 2003;28:33–36.
92. Gaertner E, Estebe JP, Zamfir A, Cuby C, Macaire P. Infraclavicular plexus block: multiple injections versus single injection. *Reg Anesth Pain Med*. 2002;27:590–594.
93. Lecamwasam H, Mayfield J, Rosow L, Chang Y, Carter C, Rosow C. Stimulation of the posterior cord predicts successful infraclavicular block. *Anesth Analg*. 2006;102:1564–1568.
94. Rodriguez J, Barcena M, Taboada-Muniz M, Lagunilla J, Alvarez J. A comparison of single versus multiple injections on the extent of anesthesia with coracoid infraclavicular brachial plexus block. *Anesth Analg*. 2004;99:1225–1230.
95. Bloc S, Garnier T, Komly B, Asfazadourian H, Leclerc P, Mercadal L, et al. Spread of injectate associated with radial or median nerve-type motor response during infraclavicular brachial-plexus block. *Reg Anesth Pain Med*. 2007;32:130–135.
96. Ootaki C, Hayashi H, Amano M. Ultrasound-guided infraclavicular brachial plexus block: an alternative technique to landmark-guided approaches. *Reg Anesth Pain Med*. 2000;25:600–604.
97. Sandu NS, Capan LM. Ultrasound-guided infraclavicular brachial plexus block. *Br J Anaesth*. 2002;89:254–259.
98. Yamamoto K, Tsubokawa T, Shibata K, Kobayashi T. Area of paresthesia as determinant of sensory block in axillary brachial plexus block. *Reg Anesth*. 1995;20:493–497.

99. Thompson G. The multiple compartment approach to brachial plexus anesthesia. *Tech Reg Anesth Pain Manag.* 1997;1:163–168.
100. Cockings E, Moore PL, Lewis RC. Transarterial brachial plexus blockade using high doses of 1.5% mepivacaine. *Reg Anesth.* 1987;12:159–164.
101. Liu FC, Liou JT, Tsai YF, Li AH, Day YY, Hui YL, et al. Efficacy of ultrasound-guided axillary brachial plexus block: a comparative study with nerve stimulator-guided method. *Chang Gung Med J.* 2005;28:396–402.
102. Koscielniak-Nielsen ZJ. Multiple injections in axillary block: where and how many? [editorial]. *Reg Anesth Pain Med.* 2006;31:192–195.
103. Rodriguez J, Taboada M, Valino C, Barcena M, Alvarez J. A comparison of stimulation patterns in axillary block: part 2. *Reg Anesth Pain Med.* 2006;31:202–205.
104. Sia S, Bartoli M. Selective ulnar nerve localization is not essential for axillary brachial plexus block using a multiple nerve stimulation technique. *Reg Anesth Pain Med.* 2001;26:12–16.
105. Sia S, Bartoli M, Lepri A, Marchini O, Ponsocchi P. Multiple-injection axillary brachial plexus block: a comparison of two methods of nerve localization—nerve stimulation versus paresthesia. *Anesth Analg.* 2000;91:647–651.
106. Guntz E, Herman P, Delbos A, Sosnowski M. The radial nerve should be blocked before the ulnar nerve during brachial plexus block at the humeral canal. *Can J Anaesth.* 2004;51:354–357.
107. Buchanan TS, Erickson JC. Selective block of the brachialis motor point. An anatomic investigation of musculocutaneous nerve branching. *Reg Anesth.* 1996;21:89–92.
108. Spence BC, Sites BD, Beach ML. Ultrasound-guided musculocutaneous nerve block: a description of a novel technique. *Reg Anesth Pain Med.* 2005;30:198–201.
109. Neal JM. Cutaneous blocks for the upper extremity. In: Hadzic A, ed. *Modern Regional Anesthesia.* New York: McGraw Hill; 2006.
110. Neal JM, Rathmell JP, Neal JM, Viscomi CM. Upper extremity blocks. In: Hines RL, ed. *Requisites in Anesthesiology: Regional Anesthesia.* Philadelphia: Elsevier Mosby; 2004.
111. Kubota Y, Koizumi T, Udagawa A, Kuroki T. Prevention of tourniquet pain by subcutaneous injection into the posterior half of the axilla. *J Plast Reconstr Aesthet Surg.* 2008;61:595–597.
112. Abram S. Central hyperalgesic effects of noxious stimulation associated with the use of tourniquets. *Reg Anesth Pain Med.* 1999;24:99–101.
113. Viscomi CM, Reese J, Rathmell JP. Medial and lateral antebrachial cutaneous nerve blocks: an easily learned regional anesthetic for forearm arteriovenous fistula surgery. *Reg Anesth.* 1996;21:2–5.
114. Selander D, Edshage S, Wolff T. Paresthesiae or no paresthesiae? Nerve lesions after axillary blocks. *Acta Anaesth Scand.* 1979;23:27–33.
115. Stan TC, Krantz MA, Solomon DL, Poulos JG, Chaouki K. The incidence of neurovascular complications following axillary brachial plexus block using a transarterial approach. *Reg Anesth.* 1995;20:486–492.
116. Schafhalter-Zoppoth I, Gray AT. Ultrasound-guided ulnar nerve block in the presence of a superficial ulnar artery. *Reg Anesth Pain Med.* 2004;29:297–298.
117. Foxall GL, Skinner D, Hardman JG, Bedford NM. Ultrasound anatomy of the radial nerve in the distal upper arm. *Reg Anesth Pain Med.* 2007;32:217–220.
118. McCartney CJ, Xu D, Constantinescu C, Abbas S, Chan VW. Ultrasound examination of peripheral nerves in the forearm. *Reg Anesth Pain Med.* 2007;32:434–439.
119. Macaire P, Singelyn F, Narchi P, Paqueron X. Ultrasound- or nerve stimulation-guided wrist blocks for carpal tunnel release: a randomized prospective comparative study. *Reg Anesth Pain Med.* 2008;33:363–368.
120. Chan VWS, Peng PWH, Kaszas Z, Middleton WJ, Muni R, Anastakis DG, et al. A comparative study of general anesthesia, intravenous regional anesthesia, and axillary block for outpatient hand surgery: clinical outcome and cost. *Anesth Analg.* 2001;93:1181–1184.
121. Hadzic A, Arliss J, Kerimoglu B, Karaca PE, Yufa M, Claudio RE, et al. A comparison of infraclavicular nerve block versus general anesthesia for hand and wrist day-case surgeries. *Anesthesiology.* 2004;101:127–132.
122. Hadzic A, Williams BA, Karaca PE, Hobeika P, Unis G, Dermksian J, et al. For outpatient rotator cuff surgery, nerve block anesthesia provides superior same-day recovery after general anesthesia. *Anesthesiology.* 2005;102:1001–1007.
123. McCartney CJ, Brull R, Chan VW, Katz J, Abbas S, Graham B, et al. Early but no long-term benefit of regional compared with general anesthesia for ambulatory hand surgery. *Anesthesiology.* 2004;101:461–467.
124. Klein SM, Grant SA, Greengrass RA, Nielsen KC, Speer KP, White W, et al. Interscalene brachial plexus block with a continuous catheter insertion system and a disposable infusion pump. *Anesth Analg.* 2000;91:1473–1478.
125. Salonen MA, Haasio J, Bachmann M, Xu M, Rosenberg PH. Evaluation of efficacy and plasma concentrations of ropivacaine in continuous axillary brachial plexus block: high dose for surgical anesthesia and low dose for postoperative analgesia. *Reg Anesth Pain Med.* 2000;25:47–51.
126. Ilfeld BM, Morey TE, Wright TW, Chidgey LK, Enneking FK. Continuous interscalene brachial plexus lock for postoperative pain control at home: a randomized, double-blinded, placebo-controlled study. *Anesth Analg.* 2003;96:1089–1095.
127. Delaunay L, Souron V, Lafosse L, Marret E, Toussaint B. Analgesia after arthroscopic rotator cuff repair: subacromial versus interscalene continuous infusion of ropivacaine. *Reg Anesth Pain Med.* 2005;30:117–122.
128. Ilfeld BM, Wright TW, Enneking FK, Vandenborne K. Total elbow arthroplasty as an outpatient procedure using a continuous infraclavicular nerve block at home: a prospective case report. *Reg Anesth Pain Med.* 2006;31:172–176.
129. Capdevila X, Dadure C, Bringuier S, Bernard N, Biboulet P, Gaertner E, et al. Effect of patient-controlled perineural analgesia on rehabilitation and pain after ambulatory orthopedic surgery. A multicenter randomized trial. *Anesthesiology.* 2006;105:566–573.
130. Kean J, Wigderowitz CA, Coventry DM. Continuous interscalene infusion and single injection block. Comparison of success rate using perivascular and nerve stimulator techniques. *J Bone Joint Surg Br.* 2006;88:1173–1177.
131. Hofmann-Kiefer K, Eiser T, Chappell D, Leuschner S, Conzen P, Schwender D. Does patient-controlled continuous interscalene block improve early functional rehabilitation after open shoulder surgery? *Anesth Analg.* 2008;106:991–996.
132. Ilfeld BM, Morey TE, Enneking FK. Continuous infraclavicular brachial plexus block for postoperative pain control at home: a randomized, double-blinded, placebo-controlled study. *Anesthesiology.* 2002;96:1297–1304.
133. Ilfeld BM, Vandenborne K, Duncan PW, Sessler DI, Enneking FK, Shuster JJ, et al. Ambulatory continuous interscalene nerve blocks decrease the time to discharge readiness after total shoulder arthroplasty. A randomized, triple-masked, placebo-controlled study. *Anesthesiology.* 2006;105:999–1007.
134. Hebl JR, Dilger JA, Byer DE, Kopp SL, Stevens SR, Pagnano MW,

- et al. A pre-emptive multimodal pathway featuring peripheral nerve block improves perioperative outcomes after major orthopedic surgery. *Reg Anesth Pain Med.* 2008;33:510–517.
135. Ritchie E, Tong D, Chung F, Norris A, Miniaci A, Vairavanathan S. Suprascapular nerve block for postoperative pain relief in arthroscopic shoulder surgery: a new modality? *Anesth Analg.* 1997;84:1306–1312.
 136. Neal JM, McDonald SB, Larkin KL, Polissar NL. Suprascapular nerve block prolongs analgesia after nonarthroscopic shoulder surgery, but does not improve outcome. *Anesth Analg.* 2003;96:982–986.
 137. Singelyn FJ, Lhotel L, Fabre B. Pain relief after arthroscopic shoulder surgery: a comparison of intraarticular analgesia, suprascapular nerve block, and interscalene brachial plexus block. *Anesth Analg.* 2004;99:589–592.
 138. Beaudet V, Williams SR, Tetreault P, Perrault M-A. Perioperative interscalene block versus intra-articular injection of local anesthetics for postoperative analgesia in shoulder surgery. *Reg Anesth Pain Med.* 2008;33:134–138.
 139. Checcucci G, Allegra A, Bigazzi P, Giansello L, Ceruso M, Gritti G. A new technique for regional anesthesia for arthroscopic shoulder surgery based on a suprascapular nerve block and an axillary block: an evaluation of the first results. *Arthroscopy.* 2008;24:689–696.
 140. Price DJ. Axillary (circumflex) nerve block used in association with suprascapular nerve block for the control of pain following total shoulder joint replacement. *Reg Anesth Pain Med.* 2008;33:280–281.
 141. Laurila PA, Lopponen A, Kanga-Saarela T, Salomaki TE. Interscalene brachial plexus block is superior to subacromial bursa block after arthroscopic shoulder surgery. *Acta Anaesthesiol Scand.* 2002;46:1031–1036.
 142. Iffeld BM, Wright TW, Enneking FK, Mace JA, Shuster JJ, Spadoni EH, et al. Total shoulder arthroplasty as an outpatient procedure using ambulatory perineural local anesthetic infusion: a pilot feasibility study. *Anesth Analg.* 2005;101:1319–1322.
 143. Iffeld BM, Wright TW, Enneking FK, Morey TE. Joint range of motion after total shoulder arthroplasty with and without a continuous interscalene nerve block: a retrospective, case-control study. *Reg Anesth Pain Med.* 2005;30:429–433.
 144. Ciccone WJ, Busey TD, Weinstein DM, Walden DL, Elias JJ. Assessment of pain relief provided by interscalene regional block and infusion pump after arthroscopic shoulder surgery. *Arthroscopy.* 2008;24:14–19.
 145. Nisar A, Morris MW, Freeman JV, Cort JM, Rayner PR, Shahane SA. Subacromial bursa block is an effective alternative to interscalene block for postoperative pain control after arthroscopic subacromial decompression: a randomized trial. *J Shoulder Elbow Surg.* 2008;17:78–84.
 146. Webb D, Guttman D, Cawley P, Lubowitz JH. Continuous infusion of local anesthetic versus interscalene block for postoperative pain control after arthroscopic shoulder surgery. *Arthroscopy.* 2007;23:1006–1011.
 147. Bigeleisen PE. Nerve puncture and apparent intraneural injection during ultrasound-guided axillary block does not invariably result in neurologic injury. *Anesthesiology.* 2006;105:779–783.
 148. Pearce H, Lindsay D, Leslie K. Axillary brachial plexus block in two hundred consecutive patients. *Anaesth Intensive Care.* 1996;24:453–458.
 149. Albert DB, Dudarevitch D, Bloom K, Rosenberg AD. Surface stimulation to determine needle direction and angle when performing an infraclavicular brachial plexus block. *Pain Pract.* 2006;6:104–106.
 150. Urmey WF, Grossi P. Percutaneous electrode guidance and subcutaneous stimulating electrode guidance: modifications of the original technique. *Reg Anesth Pain Med.* 2003;28:253–255.
 151. Ajar A, Hoeft M, Alsofrom GF, Mukerji SK, Rathmell JP. Review of brachial plexus anatomy as seen on diagnostic imaging: clinical correlation with computed tomography-guided brachial plexus block. *Reg Anesth Pain Med.* 2007;32:79–83.
 152. Choyce A, Chan VWS, Middleton WJ, Knight PR, Peng P, McCartney CJL. What is the relationship between paresthesia and nerve stimulation for axillary brachial plexus block? *Reg Anesth Pain Med.* 2001;26:100–104.
 153. Urmey WF, Stanton J. Inability to consistently elicit a motor response following sensory paresthesia during interscalene block administration. *Anesthesiology.* 2002;96:552–554.
 154. Hogan QH. Pathophysiology of peripheral nerve injury during regional anesthesia. *Reg Anesth Pain Med.* 2008;33:435–441.
 155. Neal JM. How close is close enough? Defining the “paresthesia chad” [editorial]. *Reg Anesth Pain Med.* 2001;26:97–99.
 156. Franco CD, Vieira ZE. 1,001 Subclavian perivascular brachial plexus blocks: success with a nerve stimulator. *Reg Anesth Pain Med.* 2000;25:41–46.
 157. Goldberg ME, Gregg C, Larijani GE, Norris MC, Marr AT, Seltzer JL. A comparison of three methods of axillary approach to brachial plexus blockade for upper extremity surgery. *Anesthesiology.* 1987;66:814–816.
 158. Carles M, Pulcini A, Macchi P, Duflos P, Raucoules-Aime M, Grimaud D. An evaluation of the brachial plexus block at the humeral canal using a neurostimulator (1417 patients): the efficacy, safety, and predictive criteria of failure. *Anesth Analg.* 2001;92:194–198.
 159. Franco CD, Domashevich V, Voronov G, Rafizad AB, Jelev TJ. The supraclavicular block with a nerve stimulator: to decrease or not to decrease, that is the question. *Anesth Analg.* 2004;98:1167–1171.
 160. Koscielniak-Nielsen ZJ, Hesselbjerg L, Fejlberg V. Comparison of transarterial and multiple nerve stimulation techniques for an initial axillary block by 45 mL of mepivacaine 1% with adrenaline. *Acta Anaesthesiol Scand.* 1998;42:570–575.
 161. Koscielniak-Nielsen ZJ, Rotboll Nielsen P, Sorensen T, Stenor M. Low dose axillary block by targeted injections of the terminal nerves. *Can J Anaesth.* 1999;46:658–664.
 162. Hickey R, Hoffman J, Tingle LJ, Rogers JN, Ramamurthy S. Comparison of the clinical efficacy of three perivascular techniques for axillary brachial plexus block. *Reg Anesth.* 1993;18:335–338.
 163. Perlas A, Chan VWS, Simons M. Brachial plexus examination and localization using ultrasound and electrical stimulation. *Anesthesiology.* 2003;99:429–435.
 164. Perlas A, Niazi A, McCartney C, Chan V, Xu D, Abbas S. The sensitivity of motor responses to nerve stimulation and paresthesia for nerve localization as evaluated by ultrasound. *Reg Anesth Pain Med.* 2006;31:445–450.
 165. Fredrickson MJ. The sensitivity of motor response to needle nerve stimulation during ultrasound guided interscalene catheter placement. *Reg Anesth Pain Med.* 2008;33:291–296.
 166. Chan VW, Brull R, McCartney CJ, Xu D, Abbas S, Shannon P. An ultrasonic and histologic study of intraneural injection and electrical stimulation in pigs. *Anesth Analg.* 2007;104:1281–1284.
 167. Casati A, Danelli G, Baciarello M, Corradi M, Leone S, Di Cianni S, et al. A prospective, randomized comparison between ultrasound and nerve stimulation guidance for multiple injection axillary brachial plexus block. *Anesthesiology.* 2007;106:992–996.
 168. Chan VW, Perlas A, McCartney J, Brull R, Xu D, Abbas S. Ultrasound guidance improves success rate of axillary brachial plexus block. *Can J Anaesth.* 2007;54:176–182.

169. Sites BD, Beach ML, Spence BC, Wiley CW. Ultrasound guidance improves the success rate of a perivascular axillary plexus block. *Acta Anaesthesiol Scand*. 2006;50:678–684.
170. Williams SR, Chouinard P, Arcand G, Harris P, Ruel M, Boudreault D, et al. Ultrasound guidance speeds execution and improves the quality of supraclavicular block. *Anesth Analg*. 2003;97:1518–1523.
171. Marhofer P, Sitzwohl C, Greher M, Kapral S. Ultrasound guidance for infraclavicular brachial plexus anaesthesia in children. *Anaesthesia*. 2004;59:642–646.
172. Soeding PE, Sha S, Royse CE, Marks P, Hoy G, Royse AG. A randomized trial of ultrasound-guided brachial plexus anaesthesia in upper limb surgery. *Anaesth Intensive Care*. 2005;33:719–725.
173. Dingemans E, Williams SR, Arcand G, Chouinard P, Harris P, Ruel M, et al. Neurostimulation in ultrasound-guided infraclavicular block: a prospective randomized trial. *Anesth Analg*. 2007;104:1275–1280.
174. Sauter AR, Dodgson MS, Stubhaug A, Halstensen AM, Klaastad O. Electrical nerve stimulation or ultrasound guidance for lateral sagittal infraclavicular blocks: a randomized, controlled, observer-blinded, comparative study. *Anesth Analg*. 2008;106:1910–1915.
175. Sites BD, Spence BC, Gallagher JD, Beach ML. On the edge of the ultrasound screen: regional anesthesiologists diagnosing nonneural pathology. *Reg Anesth Pain Med*. 2006;31:555–562.
176. Kessler J, Gray AT. Sonography of scalene muscle anomalies for brachial plexus block. *Reg Anesth Pain Med*. 2007;32:172–173.
177. Duggan E, Brull R, Lai J, Abbas S. Ultrasound-guided brachial plexus block in a patient with multiple glomangiomas. *Reg Anesth Pain Med*. 2008;33:70–73.
178. Manickam BP, Perlas A, Chan VWS, Brull R. The role of a preprocedure systematic sonographic survey in ultrasound-guided regional anesthesia. *Reg Anesth Pain Med*. 2008;33:566–570.
179. Abrahams MS, Panzer O, Atchabahian A, Horn J-L, Brown AR. Case report: limitations of local anesthetic spread during ultrasound-guided interscalene block. Description of an anatomic variant with clinical correlation. *Reg Anesth Pain Med*. 2008;33:357–359.
180. Assmann N, McCartney CJ, Tumber PS, Chan VW. Ultrasound guidance for brachial plexus localization and catheter insertion after complete forearm amputation. *Reg Anesth Pain Med*. 2007;32:93.
181. Orebaugh SL, Williams BA, Kentor ML. Ultrasound guidance with nerve stimulation reduces the time necessary for resident peripheral nerve blockade. *Reg Anesth Pain Med*. 2007;32:448–454.
182. Sites BD, Brull R, Chan VWS, Spence BC, Gallagher J, Beach ML, et al. Artifacts and pitfall errors associated with ultrasound-guided regional anesthesia. Part I: understanding the basic principles of ultrasound physics and machine operations. *Reg Anesth Pain Med*. 2007;32:412–418.
183. Sites BD, Brull R, Chan VWS, Spence BC, Gallagher J, Beach ML, et al. Artifacts and pitfall errors associated with ultrasound-guided regional anesthesia. Part II: a pictorial approach to understanding and avoidance. *Reg Anesth Pain Med*. 2007;32:419–433.
184. Sites BD, Spence BC, Gallagher J, Wiley CW, Bertrand ML, Blake GT. Characterizing novice behavior associated with learning ultrasound-guided peripheral regional anesthesia. *Reg Anesth Pain Med*. 2007;32:107–115.
185. Tsui BC. Facilitating needle alignment in-plane to an ultrasound beam using a portable laser unit. *Reg Anesth Pain Med*. 2007;32:84–88.
186. Sinha SK, Abrams JH, Weller RS. Ultrasound-guided interscalene needle placement produces successful anesthesia regardless of motor stimulation above or below 0.5 mA. *Anesth Analg*. 2007;105:848–852.
187. Hebl JR. Ultrasound-guided regional anesthesia and the prevention of neurologic injury: fact or fiction? [editorial]. *Anesthesiology*. 2008;108:186–188.
188. Koff MD, Cohen JA, McIntyre JJ, Carr CF, Sites BD. Severe brachial plexopathy after an ultrasound-guided single-injection nerve block for total shoulder arthroplasty in a patient with multiple sclerosis. *Anesthesiology*. 2008;108:325–328.
189. Zetlaoui RJ, Labbe J-P, Benhamou D. Ultrasound guidance for axillary plexus block does not prevent intravascular injection. *Anesthesiology*. 2008;108:761.
190. Saranteas T, Karakitsos D, Alevizou A, Poularas J, Kostopanagiotou G, Karabinis A. Limitations and technical considerations of ultrasound-guided peripheral nerve blocks: edema and subcutaneous air. *Reg Anesth Pain Med*. 2008;33:353–356.
191. Chin KJ, Perlas A, Chan VWS, Brull R. Needle visualization in ultrasound-guided regional anesthesia: challenges and solutions. *Reg Anesth Pain Med*. 2008;33:532–544.
192. Marhofer P, Sitzwohl C, Greher M, Kapral S. A randomized trial of ultrasound-guided brachial plexus anaesthesia in upper limb surgery. *Anaesth Intensive Care*. 2005;33:719–725.
193. Swenson JD, Bay N, Loose E, Bankhead B, Davis J, Beals TC, et al. Outpatient management of continuous peripheral nerve catheters placed using ultrasound guidance: an experience in 620 patients. *Anesth Analg*. 2006;103:1436–1443.
194. Fredrickson MJ, Ball CM, Dalgleish AJ. Successful continuous interscalene analgesia for ambulatory shoulder surgery in a private practice setting. *Reg Anesth Pain Med*. 2008;33:122–128.
195. Ilfeld BM, Morey TE, Enneking FK. Infraclavicular perineural local anesthetic infusion: a comparison of three dosing regimens for postoperative analgesia. *Anesthesiology*. 2004;100:395–402.
196. Borgeat A, Ekatodramis G, Dumont C. An evaluation of the infraclavicular block via a modified approach of the Raj technique. *Anesth Analg*. 2001;93:436–441.
197. Gallay SH, Lobo JJ, Baker J, Smith K, Patel K. Development of a regional model of care for ambulatory total shoulder arthroplasty: a pilot study. *Clin Orthop Relat Res*. 2008;466:563–572.
198. Pham-Dang C, Meunier J, Poirier P. A new axillary approach for continuous brachial plexus block. A clinical and anatomic study. *Anesth Analg*. 1995;81:686–693.
199. Cornish PB. Supraclavicular regional anaesthesia revisited—the bent needle technique. *Anaesth Intensive Care*. 2000;28:676–679.
200. Grant SA, Nielsen KC, Greengrass RA, Steele SM, Klein SM. Continuous peripheral nerve block for ambulatory surgery. *Reg Anesth Pain Med*. 2001;26:209–214.
201. Slater ME, Williams SR, Harris P, Brutus JP, Ruel M, Girard F, et al. Preliminary evaluation of infraclavicular catheters inserted using ultrasound guidance: through-the-needle catheter anesthesia is not inferior to through-the-needle blocks. *Reg Anesth Pain Med*. 2007;32:296–302.
202. Birnbaum J, Kip M, Spies CD, Hein OV, Labs K, Moeckel G, et al. The effect of stimulating versus non-stimulating catheters for continuous interscalene plexus blocks in short-term pain management. *J Clin Anesth*. 2007;19:434–439.
203. Tran DQH, Munoz L, Russo G, Finlayson RJ. Ultrasonography and stimulating perineural catheters for nerve blocks: a review of the evidence. *Can J Anaesth*. 2008;55:447–457.
204. Koscielniak-Nielsen ZJ, Rasmussen H, Hesselbjerg L. Long-axis ultrasound imaging of the nerves and advancement of perineural catheters under direct vision: a preliminary report of four cases. *Reg Anesth Pain Med*. 2008;33:477–482.
205. Ilfeld BM, Morey TE, Wright TW, Chidgey LK, Enneking FK. Interscalene perineural ropivacaine infusion: a comparison of

- two dosing regimens for open shoulder surgery. *Reg Anesth Pain Med.* 2004;29:9–16.
206. Le LT, Loland VJ, Mariano ER, Gerancher JC, Wadhwa AN, Renehan EM, et al. Effects of local anesthetic concentration and dose on continuous interscalene nerve blocks: a dual-center, randomized, observer-masked, controlled study. *Reg Anesth Pain Med.* 2008;33:518–525.
 207. Ilfeld BM, Morey TE, Enneking FK. Delivery rate accuracy of portable infusion pumps used for patient-controlled continuous regional anesthesia. *Reg Anesth Pain Med.* 2003;28:17–23.
 208. Ilfeld BM, Morey TE, Enneking FK. Portable infusion pumps used for continuous regional anesthesia: delivery rate accuracy and consistency. *Reg Anesth Pain Med.* 2003;28:424–432.
 209. Ilfeld BM, Morey TE, Enneking FK. New portable infusion pumps: real advantages or just more of the same in a different package? *Reg Anesth Pain Med.* 2004;29:371–376.
 210. Casati A, Fanelli G, Aldegheri G, Berti M, Colnaghi E, Cedrati V, et al. Interscalene brachial plexus anaesthesia with 0.5%, 0.75% or 1% ropivacaine: a double-blind comparison with 2% mepivacaine. *Br J Anaesth.* 1999;83:872–875.
 211. Al-Kaisy A, McGuire G, Chan V, Bruin G, Peng P, Miniaci A, et al. Analgesic effect of interscalene block using low-dose bupivacaine for outpatient arthroscopic shoulder surgery. *Reg Anesth Pain Med.* 1998;23:469–473.
 212. Krone SC, Chan VW, Regan J, Peng P, Poate EM, McCartney CJ, et al. Analgesic effects of low-dose ropivacaine for interscalene brachial plexus block for outpatient shoulder surgery—a dose-finding study. *Reg Anesth Pain Med.* 2001;26:439–443.
 213. Hickey R, Rowley CL, Candido KD, Hoffman J, Ramamurthy S, Winnie AP. A comparative study of 0.25% ropivacaine and 0.25% bupivacaine for brachial plexus block. *Anesth Analg.* 1992;75:602–606.
 214. Casati A, Fanelli G, Cappelleri G, Beccaria P, Magistis L, Borghi B, et al. A clinical comparison of ropivacaine 0.75%, ropivacaine 1% or bupivacaine 0.5% for interscalene brachial plexus anaesthesia. *Eur J Anaesthesiol.* 1999;16:784–789.
 215. Klein SM, Greengrass RA, Steele SM, D'Ercole FJ, Speer KP, Gleason DH, et al. A comparison of 0.5% bupivacaine, 0.5% ropivacaine, and 0.75% ropivacaine for interscalene brachial plexus block. *Anesth Analg.* 1998;87:1316–1319.
 216. Cox CR, Checketts MR, Mackenzie N, Scott NB, Bannister J. Comparison of S(–)-bupivacaine with racemic (RS)-bupivacaine in supraclavicular brachial plexus block. *Br J Anaesth.* 1998;80:594–598.
 217. Casati A, Borghi B, Fanelli G, Montone N, Rotini R, Fraschini G, et al. Interscalene brachial plexus anesthesia and analgesia for open shoulder surgery: a randomized, double-blinded comparison between levobupivacaine and ropivacaine. *Anesth Analg.* 2003;96:253–259.
 218. Rawal N, Allvin R, Axelsson K, Hallen J, Ekback G, Ohlsson T, et al. Patient-controlled regional analgesia (PCRA) at home: controlled comparison between bupivacaine and ropivacaine brachial plexus analgesia. *Anesthesiology.* 2002;96:1290–1296.
 219. Borgeat A, Kalberer F, Jacob H, Ruetsch YA, Gerber C. Patient-controlled interscalene analgesia with ropivacaine 0.2% versus bupivacaine 0.15% after major open shoulder surgery: the effects on hand motor function. *Anesth Analg.* 2001;92:218–223.
 220. Popitz-Bergez FA, Leeson S, Strichartz GR, Thalhammer JG. Relation between functional deficit and intraneural local anesthetic during peripheral nerve block: a study in the rat sciatic nerve. *Anesthesiology.* 1995;83:583–592.
 221. Fink BR, Aasheim G, Kish SJ, Croley TS. Neurokinetics of lidocaine in the infraorbital nerve of the rat in vivo: relation to sensory block. *Anesthesiology.* 1975;42:731–736.
 222. Raymond SA, Steffenson SC, Gugino LD, Strichartz GR. The role of length of nerve exposed to local anesthetics in impulse blocking action. *Anesth Analg.* 1989;68:563–570.
 223. Vester-Andersen T, Christiansen C, Sorensen M, Eriksen C. Perivascular axillary block I: blockade following 40 mL 1% mepivacaine with adrenaline. *Acta Anaesthesiol Scand.* 1982;26:519–523.
 224. Vester-Andersen T, Christiansen C, Sorensen M, Kaalund-Jorgensen HO, Saugbjerg P, Schultz-Moller K. Perivascular axillary block II: influence of injected volume of local anesthetic on neural blockade. *Acta Anaesthesiol Scand.* 1983;27:95–98.
 225. Vester-Andersen T, Eriksen C, Christiansen C. Perivascular axillary block III: blockade following 40 mL of 0.5%, 1% or 1.5% mepivacaine with adrenaline. *Acta Anaesthesiol Scand.* 1984;28:95–98.
 226. Vester-Andersen T, Husum B, Lindeburg T, Borrits L, Gothgen I. Perivascular axillary block IV: blockade following 40, 50 or 60 mL of mepivacaine 1% with adrenaline. *Acta Anaesthesiol Scand.* 1984;28:99–105.
 227. Vester-Andersen T, Husum B, Lindeburg T, Borrits L, Gothgen I. Perivascular axillary block V: blockade following 60 mL of mepivacaine 1% injected as a bolus or as 30+30 mL with a 20-min interval. *Acta Anaesthesiol Scand.* 1984;28:612–616.
 228. Serradell A, Herrero R, Villanueva JA, Santos JA, Moncho JM, Masdeu J. Comparison of three different volumes of mepivacaine in axillary plexus block using multiple nerve stimulation. *Br J Anaesth.* 2003;91:519–524.
 229. Riaz S, Carmichael N, Awad I, Holtby RM, McCartney CJL. Effect of local anaesthetic volume (20 vs 5 mL) on the efficacy and respiratory consequences of ultrasound-guided interscalene brachial plexus block. *Br J Anaesth.* 2008;101:549–556.
 230. Krenn H, Deusch E, Balogh B, Jellinek H, Oczenski W, Plainer-Zochling E, et al. Increasing the injection volume by dilution improves the onset of motor blockade, but not sensory blockade of ropivacaine for brachial plexus block. *Eur J Anaesth.* 2003;20:21–25.
 231. Fuzier R, Fourcade O, Fuzier V, Gonzalez H, Albert N, Riviere D, et al. Characteristics of mepivacaine axillary brachial plexus block performed at 2800 m of altitude [in French]. *Ann Fr Anesth Reanim.* 2007;26:17–22.
 232. Crews JC, Weller RS, Moss J, James RL. Levobupivacaine for axillary brachial plexus block: a pharmacokinetic and clinical comparison in patients with normal renal function or renal disease. *Anesth Analg.* 2002;95:219–223.
 233. Pere P, Salonen M, Jokinen M, Rosenberg PH, Haasio J. Pharmacokinetics of ropivacaine in uremic and nonuremic patients after axillary brachial plexus block. *Anesth Analg.* 2003;96:563–569.
 234. Iohom G, Machmachi A, Desire-Pascal D, Khatouf M, Boileau S, Dap F, et al. The effects of clonidine added to mepivacaine for paronychia surgery under axillary brachial plexus block. *Anesth Analg.* 2005;100:1179–1183.
 235. Covino BG, Wildsmith JAW. Clinical pharmacology of local anesthetic agents. In: Cousins MJ, Bridenbaugh PO, eds. *Neural Blockade in Clinical Anesthesia and Management of Pain.* 3rd ed. Philadelphia: Lippincott-Raven Publishers; 1998:97–128.
 236. Martin R, Dumais R, Cinq-Mars S, Tetraut JP. Bloc axillaire par blocage simultané de plusieurs nerfs II. Evaluation du mélange lidocaine-bupivacaine. *Ann Fr Anesth Reanim.* 1993;12:233–236.
 237. Spiegel D, Dexter F, Warner DS, Baker MT, Todd MM. Central nervous system toxicity of local anesthetic mixtures in the rat. *Anesth Analg.* 1992;75:922–928.
 238. Iskandar H, Guillaume E, Dixmerias F, Binje B, Rakotondriamihary S, Thiebaut R, et al. The enhancement of sensory blockade by clonidine selectively added to mepivacaine after midhumeral block. *Anesth Analg.* 2001;93:771–775.

239. Bouaziz H, Narchi P, Mercier FJ, Khoury A, Poirier T, Benhamou D. The use of selective axillary nerve block for outpatient hand surgery. *Anesth Analg*. 1998;86:746–748.
240. Butterworth JF IV, Walker FO, Neal JM. Cooling potentiates lidocaine inhibition of median nerve sensory fibers. *Anesth Analg*. 1990;70:507–511.
241. Heath PJ, Brownlie GS, Herrick MJ. Latency of brachial plexus block. The effect on onset time of warming local anaesthetic solutions. *Anaesthesia*. 1990;45:297–301.
242. Chilvers CR. Warm local anaesthetic—effect on latency of axillary brachial plexus block. *Anaesth Intensive Care*. 1993;21:795–798.
243. Okasha AS, El Attar AM, Soliman HL. Enhanced brachial plexus blockade. Effect of pain and muscular exercise on the efficiency of brachial plexus blockade. *Anaesthesia*. 1988;43:327–329.
244. Stevens MF, Linstedt U, Neruda B, Lipfert P, Wulf H. Effect of transcutaneous electrical nerve stimulation on onset of axillary plexus block. *Anaesthesia*. 1996;51:916–919.
245. Rucci FS, Pippa P, Boccaccini A, Barbagli R. Effect of injection speed on anaesthetic spread during axillary block using the orthogonal two-needle technique. *Eur J Anaesthesiol*. 1995;12:505–511.
246. Sala-Blanch X, Lazaro JR, Correa J, Gomez-Fernandez M. Phrenic nerve block caused by interscalene brachial plexus block: effects of digital pressure and a low volume of local anesthetic. *Reg Anesth Pain Med*. 1999;24:231–235.
247. Yamamoto K, Tsubokawa T, Ohmura S, Kobayashi T. The effects of arm position on central spread of local anesthetics and on quality of the block with axillary brachial plexus block. *Reg Anesth Pain Med*. 1999;24:36–42.
248. Ababou A, Marzouk N, Mosadiq A, Sbihi A. The effects of arm position on onset and duration of axillary brachial plexus block. *Anesth Analg*. 2007;104:980–981.
249. Tetzlaff JE, Yoon HJ, O'Hara JF, Reaney J, Stein D, Grimes-Rice M. Alkalinization of mepivacaine accelerates onset of interscalene block for shoulder surgery. *Reg Anesth*. 1990;15:242–244.
250. Tetzlaff JE, Yoon HJ, Brems J, Javorsky T. Alkalinization of mepivacaine improves the quality of motor block associated with interscalene brachial plexus anesthesia for shoulder surgery. *Reg Anesth*. 1995;20:128–132.
251. Sukhani R, Winnie AP. Clinical pharmacokinetics of carbonated local anesthetics. II: Interscalene brachial block model. *Anesth Analg*. 1987;66:1245–1250.
252. Chow MYH, Sia ATH, Koay CK, Chan YW. Alkalinization of lidocaine does not hasten the onset of axillary brachial plexus block. *Anesth Analg*. 1998;86:566–568.
253. Quinlan JJ, Oleksey K, Murphy FL. Alkalinization of mepivacaine for axillary block. *Anesth Analg*. 1992;74:371–374.
254. Sinnott CJ, Garfield JM, Thalhammer JG, Strichartz GR. Addition of sodium bicarbonate to lidocaine decreases the duration of peripheral nerve block in the rat. *Anesthesiology*. 2000;93:1045–1052.
255. Rose JS, Neal JM, Kopacz DJ. Extended-duration analgesia: update on microspheres and liposomes. *Reg Anesth Pain Med*. 2005;30:275–285.
256. Bernards CM, Kopacz DJ. Effect of epinephrine on lidocaine clearance in vivo: a microdialysis study in humans. *Anesthesiology*. 1999;91:962–968.
257. Hickey R, Blanchard J, Hoffman J, Sjovall J, Ramamurthy S. Plasma concentrations of ropivacaine given with or without epinephrine for brachial plexus block. *Can J Anaesth*. 1990;37:878–882.
258. Dogru K, Duygulu F, Yildiz K, Kotanoglu MS, Madenoglu H, Boyaci A. Hemodynamic and blockade effects of high/low epinephrine doses during axillary brachial plexus blockade with lidocaine 1.5%: a randomized, double-blind study. *Reg Anesth Pain Med*. 2003;28:401–405.
259. Kennedy WF, Bonica JJ, Ward RJ, Tolas AG, Martin WE, Grinstein A. Cardiorespiratory effects of epinephrine when used in regional anesthesia. *Acta Anaesthesiol Scand*. 1966;23:320–333.
260. Partridge BL. The effects of local anesthetics and epinephrine on rat sciatic nerve blood flow. *Anesthesiology*. 1991;75:243–251.
261. Neal JM. Effects of epinephrine in local anesthetics on the central and peripheral nervous systems: neurotoxicity and neural blood flow. *Reg Anesth Pain Med*. 2003;28:124–134.
262. Denkler K. A comprehensive review of epinephrine in the finger: to do or not to do. *Plast Reconstr Surg*. 2001;108:114–124.
263. McCartney CJL, Duggan E, Apatu E. Should we add clonidine to local anesthetic for peripheral nerve blockade? A qualitative systematic review of the literature. *Reg Anesth Pain Med*. 2007;32:330–338.
264. Singelyn FJ, Dangoisse M, Bartholomee S, Gouverneur J-M. Adding clonidine to mepivacaine prolongs the duration of anesthesia and analgesia after axillary brachial plexus block. *Reg Anesth*. 1992;17:148–150.
265. Singelyn FJ, Gouverneur J-M, Robert A. A minimum dose of clonidine added to mepivacaine prolongs the duration of anesthesia and analgesia after axillary brachial plexus block. *Anesth Analg*. 1996;83:1046–1050.
266. Bernard J-M, Macaire P. Dose-range effects of clonidine added to lidocaine for brachial plexus block. *Anesthesiology*. 1997;87:277–284.
267. Buttner J, Ott B, Klose R. The effect of adding clonidine to mepivacaine. Axillary brachial plexus blockade. *Anaesthesist*. 1992;41:548–554.
268. Eledjam JJ, Deschodt J, Viel EJ, Lubrano JF, Charavel P, d'Athis F, et al. Brachial plexus block with bupivacaine: effects of added alpha adrenergic agonists: comparison between clonidine and epinephrine. *Can J Anaesth*. 1991;38:870–875.
269. Eisenach JC, De Kock M, Klimscha W. Alpha 2-adrenergic agonists for regional anesthesia. A clinical review of clonidine (1984–1995). *Anesthesiology*. 1996;85:655–674.
270. Ilfeld BM, Morey TE, Enneking FK. Continuous infraclavicular perineural infusion with clonidine and ropivacaine compared with ropivacaine alone: a randomized, double-blind, controlled study. *Anesth Analg*. 2003;97:706–712.
271. Gaumann DM, Forster A, Griessen M, Habre W, Poinot O, Della Santa D. Comparison between clonidine and epinephrine admixture to lidocaine in brachial plexus block. *Anesth Analg*. 1992;75:69–74.
272. Kopacz DJ, Bernards CM. Effect of clonidine on lidocaine clearance in vivo. *Anesthesiology*. 2001;95:1171–1176.
273. Reuben SS, Reuben JP. Brachial plexus anesthesia with verapamil and/or morphine. *Anesth Analg*. 2000;91:379–383.
274. Candido KD, Winnie AP, Ghaleb AH, Fattouh MW, Franco CD. Buprenorphine added to the local anesthetic for axillary brachial plexus block prolongs postoperative analgesia. *Reg Anesth Pain Med*. 2002;27:162–167.
275. Bourke DL, Furman WR. Improved postoperative analgesia with morphine added to axillary block solution. *J Clin Anesth*. 1993;5:114–117.
276. Kardash K, Schools A, Conception M. Effects of brachial plexus fentanyl on supraclavicular block. *Reg Anesth*. 1995;20:311–315.
277. Racz H, Gunning K, Della Santa D, Forster A. Evaluation of the effect of perineural morphine on the quality of postoperative analgesia after axillary block: a randomized double-blind study. *Anesth Analg*. 1991;72:769–772.
278. Murphy DB, McCartney CJL, Chan VWS. Novel analgesic

- adjuncts for brachial plexus block: a systematic review. *Anesth Analg*. 2000;2000:1122–1128.
279. Apan A, Basar H, Ozcan S, Buyukkocak U. Combination of adenosine with prilocaine and lignocaine for brachial plexus block does not prolong postoperative analgesia. *Anaesth Intensive Care*. 2003;31:648–652.
 280. Robaux S, Blunt C, Viel E, Cuvillon P, Nougier P, Dautel G, et al. Tramadol added to 1.5% mepivacaine for axillary brachial plexus block improves postoperative analgesia dose-dependently. *Anesth Analg*. 2004;98:1172–1177.
 281. Altunkaya H, Ozer Y, Kargi E, Babuccu O. Comparison of local anesthetic effects of tramadol with prilocaine for minor surgical procedures. *Br J Anaesth*. 2003;90:320–322.
 282. Bouaziz H, Paqueron X, Bur ML, Merle M, Laxenaire MC, Benhamou D. No enhancement of sensory and motor blockade by neostigmine added to mepivacaine axillary plexus block. *Anesthesiology*. 1999;91:79–83.
 283. Movafegh A, Razazian M, Hajimaohamadi F, Meysamie A. Dexamethasone added to lidocaine prolongs axillary brachial plexus block. *Anesth Analg*. 2006;102:263–267.
 284. Williams BA, Murinson BB, Grable BR, Orebaugh SL. Future considerations for pharmacologic adjuvants in single-injection peripheral nerve blocks for patients with diabetes mellitus. *Reg Anesth Pain Med*. 2009. In press.
 285. Lee IO, Kim WK, Kong MH, Lee MK, Kim NS, Choi YS, et al. No enhancement of sensory or motor blockade by ketamine added to ropivacaine interscalene brachial plexus blockade. *Acta Anaesthesiol Scand*. 2002;46:821–826.
 286. Gunduz A, Bilir A, Gulec S. Magnesium added to prilocaine prolongs the duration of axillary plexus block. *Reg Anesth Pain Med*. 2006;31:233–236.
 287. Jarbo K, Batra YK, Panda NB. Brachial plexus block with midazolam and bupivacaine improves analgesia. *Can J Anaesth*. 2005;52:822–826.
 288. Lavand'homme P. Lessons from spinal midazolam: when misuse of messages from preclinical models exposes patients to unnecessary risks [editorial]. *Reg Anesth Pain Med*. 2006;31:489–491.
 289. Keeler JF, Simpson KH, Ellis FR, Kay SP. Effect of addition of hyaluronidase to bupivacaine during axillary brachial plexus block. *Br J Anaesth*. 1992;68:68–71.
 290. Steinberg RB, Reuben SS, Gardner G. The dose-response relationship of ketorolac as a component of intravenous regional anesthesia with lidocaine. *Anesth Analg*. 1998;86:791–793.
 291. Auroy Y, Benhamou D, Bagues L, Ecoffey C, Falissard B, Mercier F, et al. Major complications of regional anesthesia in France. The SOS regional anesthesia hotline service. *Anesthesiology*. 2002;97:1274–1280.
 292. Auroy Y, Narchi P, Messiah A, Litt L, Rouvier B, Samii K. Serious complications related to regional anesthesia. Results of a prospective survey in France. *Anesthesiology*. 1997;87:479–486.
 293. Borgeat A, Ekatomdramis G, Kalberer F, Benz C. Acute and nonacute complications associated with interscalene block and shoulder surgery. A prospective study. *Anesth Analg*. 2001;95:875–880.
 294. Candido KD, Sukhani R, Doty R, Nader A, Kendall MC, Yaghmour E, et al. Neurologic sequelae after interscalene brachial plexus block for shoulder/upper arm surgery: the association of patient, anesthetic, and surgical factors to the incidence and clinical course. *Anesth Analg*. 2005;100:1489–1495.
 295. Cheney FW, Domino KB, Caplan RA, Posner KL. Nerve injury associated with anesthesia: a closed claims analysis. *Anesthesiology*. 1999;90:1062–1069.
 296. Cooper K, Kelley H, Carrithers J. Perceptions of side effects following axillary block used for outpatient surgery. *Reg Anesth*. 1995;20:212–216.
 297. Hebl JR, Horlocker TT, Sorenson EJ, Schroeder DR. Regional anesthesia does not increase the risk of postoperative neuropathy in patients undergoing ulnar nerve transposition. *Anesth Analg*. 2001;93:1606–1611.
 298. Lee L, Posner KL, Chaney FW, Caplan RA, Domino KB. Complications associated with eye blocks and peripheral nerve blocks: an ASA closed-claims analysis. *Reg Anesth Pain Med*. 2008;33:416–422.
 299. Lee LA, Posner KL, Domino KB, Caplan RA, Cheney FW. Injuries associated with regional anesthesia in the 1980s and 1990s. *Anesthesiology*. 2004;101:143–152.
 300. Liguori GA, Zayas VM, YaDeau JT, Kahn RL, Paroli L, Buschiazio V, et al. Nerve localization techniques for interscalene brachial plexus blockade: a prospective, randomized comparison of mechanical paresthesia versus electrical stimulation. *Anesth Analg*. 2006;103:761–777.
 301. Urban MK, Urquhart B. Evaluation of brachial plexus anesthesia for upper extremity surgery. *Reg Anesth*. 1994;19:175–182.
 302. Horlocker TT, Kufner RP, Bishop AT, Maxson PM, Schroeder DR. The risk of persistent paresthesia is not increased with repeated axillary block. *Anesth Analg*. 1999;88:382–387.
 303. Hebl JR. Peripheral nerve injury. In: Neal JM, Rathmell JP, eds. *Complications in Regional Anesthesia and Pain Medicine*. Philadelphia: Saunders Elsevier; 2007:125–140.
 304. Upton AR, McComas AJ. The double crush in nerve entrapment syndromes. *Lancet*. 1973;2:359–362.
 305. Neal JM, Bernards CM, Hadzic A, Hebl JR, Hogan QH, Horlocker TT, et al. ASRA Practice Advisory on neurologic complications in regional anesthesia and pain medicine. *Reg Anesth Pain Med*. 2008;33:404–422.
 306. Hebl JR, Horlocker TT, Pritchard DJ. Diffuse brachial plexopathy after interscalene blockade in a patient receiving cisplatin chemotherapy: the pharmacologic double crush syndrome. *Anesth Analg*. 2001;92:249–251.
 307. Rice ASC, McMahon SB. Peripheral nerve injury caused by injection needles used in regional anaesthesia: influence of bevel configuration, studied in a rat model. *Br J Anaesth*. 1992;69:433–438.
 308. Selander D. Catheter technique in axillary plexus block. *Acta Anaesthesiol Scand*. 1977;21:324–329.
 309. Winchell SW, Wolfe R. The incidence of neuropathy following upper extremity nerve blocks. *Reg Anesth*. 1985;10:12–15.
 310. Selander D, Ghuner K-G, Lundborg G. Peripheral nerve injury due to injection needles used for regional anesthesia. An experimental study of the acute effects of needle point trauma. *Acta Anaesthesiol Scand*. 1977;21:182–188.
 311. Winnie AP. Does the transarterial technique of axillary block provide a higher success rate and lower complication rate than a paresthesia technique? *Reg Anesth*. 1995;20:482–485.
 312. Moore DC. "No paresthesia–no anesthesia," the nerve stimulator or neither. *Reg Anesth*. 1997;22:388–390.
 313. Bernards CM, Hadzic A, Suresh S, Neal JM. Regional anesthesia in anesthetized or heavily sedated patients. *Reg Anesth Pain Med*. 2008;33:449–460.
 314. Hadzic A, Dilberovic F, Shah S, Kulenovic A, Kapur E, Zaciragic A, et al. Combination of intraneural injection and high injection pressure leads to fascicular injury and neurologic deficits in dogs. *Reg Anesth Pain Med*. 2004;29:417–423.
 315. Claudio R, Hadzic A, Shih H, Vloka JD, Castro J,

- Koscielniak-Nielsen Z, et al. Injection pressures by anesthesiologists during simulated peripheral nerve block. *Reg Anesth Pain Med*. 2004;29:201–205.
316. Tsui BC, Knezevich MP, Pillay JJ. Reduced injection pressures using a compressed air injection technique (CAIT): an in vitro study. *Reg Anesth Pain Med*. 2008;33:168–173.
317. Lundborg G. Ischemic nerve injury. *Scand J Plast Reconstr Surg*. 1970;6S:7–47.
318. Myers RR, Heckman HM. Effects of local anesthesia on nerve blood flow: studies using lidocaine with and without epinephrine. *Anesthesiology*. 1989;71:757–762.
319. Bouaziz H, Iohom G, Estebe JP, Campana WM, Meyers RR. Effects of levobupivacaine and ropivacaine on rat sciatic nerve blood flow. *Br J Anaesth*. 2005;95:696–700.
320. Selander D, Brattsand R, Lundborg G, Nordborg C, Olsson Y. Local anesthetics: importance of mode of application, concentration and adrenaline for the appearance of nerve lesions. *Acta Anaesthesiol Scand*. 1979;23:127–136.
321. Schneider U, Jund R, Nees S, Grafe P. Differences in sensitivity to hyperglycemic hypoxia of isolated rat sensory and motor nerve fibers. *Ann Neurol*. 1992;31:605–610.
322. Selander D, Sjostrand J. Longitudinal spread of intraneurally injected local anesthetics. An experimental study of the initial neural distribution following intraneural injections. *Acta Anaesthesiol Scand*. 1978;22:622–634.
323. Myers RR, Kalichman MW, Reisner LS, Powell HC. Neurotoxicity of local anesthetics: altered perineural permeability, edema, and nerve fiber injury. *Anesthesiology*. 1986;64:29–35.
324. Kalichman MW, Moorehouse DF, Powell HC, Myers RR. Relative neural toxicity of local anesthetics. *J Neuropathol Exp Neurol*. 1993;52:234–240.
325. Gentili F, Hudson AR, Hunter D, Kline DG. Nerve injection injury with local anesthetic agents: a light and electron microscopic, fluorescent microscopic, and horseradish peroxidase study. *Neurosurgery*. 1980;6:263–272.
326. Kroin JS, Penn RD, Levy FE, Kerns JM. Effect of repetitive lidocaine infusion on peripheral nerve. *Exp Neurol*. 1986;94:166–173.
327. Kyatta J, Heinonen E, Rosenberg PH, Wahlstrom T, Gripenberg J, Huopaniemi T. Effects of repeated bupivacaine administration on sciatic nerve and surrounding muscle tissue in rats. *Acta Anaesthesiol Scand*. 1986;30:625–629.
328. Neal JM, Rathmell JP. *Complications in Regional Anesthesia and Pain Medicine*. New York: Elsevier Saunders; 2007.
329. Iohom G, Lan GB, Diarra D-P, Grignon F, Merle M, Granier G, et al. Long-term evaluation of motor function following intraneural injection of ropivacaine using walking track analysis in rats. *Br J Anaesth*. 2005;94:524–529.
330. Greenblatt GM, Denson JS. Needle nerve stimulator-locator: nerve blocks with a new instrument for location of nerves. *Anesth Analg*. 1962;41:599–602.
331. Baranowski AP, Pither CE. A comparison of three methods of axillary brachial plexus anaesthesia. *Anaesthesia*. 1990;45:362–365.
332. Sia S, Lepri A, Ponzecchi P. Axillary brachial plexus block using peripheral nerve stimulator: a comparison between double- and triple-injection techniques. *Reg Anesth Pain Med*. 2001;26:499–503.
333. Benumof JL. Permanent loss of cervical spinal cord function associated with interscalene block performed under general anesthesia. *Anesthesiology*. 2000;93:1541–1544.
334. Tsai TP, Vuckovic I, Dilberovic F, Obhodzas M, Kapur E, Divanovic KA, et al. Intensity of the stimulating current may not be a reliable indicator of intraneural needle placement. *Reg Anesth Pain Med*. 2008;33:207–210.
335. Sorenson EJ. Neurological injuries associated with regional anesthesia. *Reg Anesth Pain Med*. 2008;33:442–448.
336. Brull R, McCartney CJL, Chan VWS, Liguori GA, Hargett MJ, Xu D, et al. Disclosure of risks associated with regional anesthesia: a survey of academic regional anesthesiologists. *Reg Anesth Pain Med*. 2007;32:7–11.
337. Brull R, Wijayatilake DS, Perlas A, Chan VWS, Abbas S, Liguori GA, et al. Practice patterns related to block selection, nerve localization and risk disclosure: a survey of the American Society of Regional Anesthesia and Pain Medicine. *Reg Anesth Pain Med*. 2008;33:395–403.
338. al-Kaisy AA, Chan VW, Perlas A. Respiratory effects of low-dose bupivacaine interscalene block. *Br J Anaesth*. 1999;82:217–220.
339. Singelyn FJ, Suguy S, Gouverneur JM. Interscalene brachial plexus analgesia after open shoulder surgery: continuous versus patient-controlled infusion. *Anesth Analg*. 1999;89:1216–1220.
340. Urmei W, McDonald M. Hemidiaphragmatic paresis during interscalene brachial plexus block: effects on pulmonary function and chest wall mechanics. *Anesth Analg*. 1992;74:352–357.
341. Urmei WF, Gloeggler PJ. Pulmonary function changes during interscalene brachial plexus block: effects of decreasing local anesthetic injection volume. *Reg Anesth*. 1993;18:244–249.
342. Urmei WF, Talts KH, Sharrock NE. One hundred percent incidence of hemidiaphragmatic paresis associated with interscalene brachial plexus anesthesia as diagnosed by ultrasonography. *Anesth Analg*. 1991;72:498–503.
343. Sinha S, Abrams J, Weller RS. Low vs. high volume ultrasound-guided interscalene block: pulmonary function and diaphragmatic motion. *Reg Anesth Pain Med*. 2008;33:A3.
344. Pere P. The effect of continuous interscalene brachial plexus block with 0.125% bupivacaine plus fentanyl on diaphragmatic motility and ventilatory function. *Reg Anesth*. 1993;18:93–97.
345. Casati A, Fanelli G, Cedrati V, Berti M, Aldegheri G, Torri G. Pulmonary function changes after interscalene brachial plexus anesthesia with 0.5% and 0.75% ropivacaine: a double blind comparison with 2% mepivacaine. *Anesth Analg*. 1999;88:587–592.
346. Altintas F, Gumus F, Kaya G, Mihmanli I, Kantarci F, Kaynak K, et al. Interscalene brachial plexus block with bupivacaine and ropivacaine in patients with chronic renal failure: diaphragmatic excursion and pulmonary function changes. *Anesth Analg*. 2005;100:1166–1171.
347. Capdevila X, Pirat P, Bringuier S, Gaertner E, Singelyn FJ, Bernard N, et al. Continuous peripheral nerve blocks in hospital wards after orthopedic surgery. *Anesthesiology*. 2005;103:1035–1045.
348. Sardesai AM, Chakrabarti AJ, Denny NM. Lower lobe collapse during continuous interscalene brachial plexus local anesthesia at home. *Reg Anesth Pain Med*. 2004;29:65–68.
349. Borgeat A, Perschak H, Bird P, Hodler J, Gerber C. Patient-controlled interscalene analgesia with ropivacaine 0.2% versus patient-controlled intravenous analgesia after major shoulder surgery. Effects on diaphragmatic and respiratory function. *Anesthesiology*. 2000;92:102–108.
350. Neal JM, Moore JM, Kopacz DJ, Liu SS, Kramer DJ, Plorde JJ. Quantitative analysis of respiratory, motor, and sensory function after supraclavicular block. *Anesth Analg*. 1998;86:1239–1244.
351. Mak PH, Irwin MG, Ooi CG, Chow BF. Incidence of diaphragmatic paralysis following supraclavicular brachial plexus block and its effect on pulmonary function. *Anaesthesia*. 2001;56:352–356.
352. Rodriguez J, Barcena M, Rodriguez V, Aneiros F, Alvarez J. Infraclavicular brachial plexus block effects on respiratory function and extent of block. *Reg Anesth Pain Med*. 1998;23:564–568.
353. Dullenkopf A, Blumenthal S, Theodorou P, Roos J, Perschak H, Borgeat A. Diaphragmatic excursion and respiratory function after

- the modified Raj technique of infraclavicular plexus block. *Reg Anesth Pain Med.* 2004;29:110–114.
354. Gentili ME, Deleuze A, Estebe JP, Lebourg M, Ecoffey C. Severe respiratory failure after infraclavicular block with 0.75% ropivacaine: a case report. *J Clin Anesth.* 2002;14:459–461.
 355. Bashein G, Robertson HT, Kennedy WF. Persistent phrenic nerve paresis following interscalene brachial plexus block. *Anesthesiology.* 1985;63:102–104.
 356. Ediale KR, Myung CR, Neuman GG. Prolonged hemidiaphragmatic paralysis following interscalene brachial plexus block. *J Clin Anesth.* 2004;16:573–575.
 357. Robaux S, Bouaziz H, Boisseau N, Raucoles-Aime M, Laxenaire M. Persistent phrenic nerve paralysis following interscalene brachial plexus block. *Anesthesiology.* 2001;95:1519–1521.
 358. Homer JR, Davies JM, Amundsen LB. Persistent hiccups after attempted interscalene brachial plexus block. *Reg Anesth Pain Med.* 2005;30:574–576.
 359. Desroches J. The infraclavicular brachial plexus block by the coracoid approach is clinically effective. *Can J Anaesth.* 2003;50:253–257.
 360. Neuberger M, Landes H, Kaiser H. Vertical infraclavicular block. *Anaesthesist.* 1990;49:901–904.
 361. Urmei WF. Pulmonary complications. In: Neal JM, Rathmell JP, eds. *Complications in Regional Anesthesia and Pain Medicine.* Philadelphia: Saunders Elsevier; 2007:147–156.
 362. Klaastad O, VadeBoncouer TR, Tillung T, Smedby O. An evaluation of the supraclavicular plumb-bob technique for brachial plexus block by magnetic resonance imaging. *Anesth Analg.* 2003;96:862–867.
 363. Franco CD, Gloss FJ, Voronov G, Tyler SG, Stojiljkovic LS. Supraclavicular block in the obese population: an analysis of 2020 blocks. *Anesth Analg.* 2006;102:1252–1254.
 364. Kulenkampff D, Persky MA. Brachial plexus anesthesia: its indications, technic, and dangers. *Ann Surg.* 1928;87:883.
 365. Soares LG, Brull R, Lai J, Chan VW. Eight ball, corner pocket: the optimal position for ultrasound-guided supraclavicular block [letter]. *Reg Anesth Pain Med.* 2007;32:94–95.
 366. Moore DC, Bridenbaugh LD. Pneumothorax. Its incidence following brachial plexus block analgesia. *Anesthesiology.* 1954;15:475–479.
 367. Loubert C, Williams SR, Helie F, Arcand G. Complication during ultrasound-guided regional block: accidental intravascular injection of local anesthetic. *Anesthesiology.* 2008;108:759–760.
 368. Korevaar WC, Burney RG, Moore PA. Convulsions during stellate ganglion block. *Anesth Analg.* 1979;58:329–330.
 369. McLean D, Chambers WA, Tucker GT, Wildsmith JAW. Plasma prilocaine concentrations after three techniques of brachial plexus blockade. *Br J Anaesth.* 1969;60:136–142.
 370. Scott DB. Evaluation of the toxicity of local anaesthetic agents in man. *Br J Anaesth.* 1975;47:56.
 371. Ekatodramis G, Borgeat A, Huledal G, Jeppsson L, Westman L, Sjoval J. Continuous interscalene analgesia with ropivacaine 2 mg/mL after major shoulder surgery. *Anesthesiology.* 2003;98:143–150.
 372. Denson DD, Raj PP, Saldanha F, Finnsson RA, Ritschel WA, Joyce TH, et al. Continuous perineural infusion of bupivacaine for prolonged analgesia: pharmacokinetic considerations. *Int J Clin Pharmacol Ther Toxicol.* 1983;21:591–597.
 373. Mather LE, Copeland SE, Ladd LA. Acute toxicity of local anesthetics: underlying pharmacokinetic and pharmacodynamic concepts. *Reg Anesth Pain Med.* 2005;30:553–566.
 374. Rosenberg P, Veering BT, Urmei WF. Maximum recommended doses of local anesthetics: a multifactorial concept. *Reg Anesth Pain Med.* 2004;29:564–575.
 375. Mulroy MF, Norris MC, Liu SS. Safety steps for epidural injection of local anesthetics: review of the literature and recommendations. *Anesth Analg.* 1997;85:1346–1356.
 376. Brown DL, Ransom DM, Hall JA, Leicht CH, Schroeder DR, Offord KP. Regional anesthesia and local anesthetic-induced systemic toxicity: seizure frequency and accompanying cardiovascular changes. *Anesth Analg.* 1995;81:321–328.
 377. Jandard C, Gentilli ME, Girard F, Ecoffey C, Heck M, Laxenaire MC, et al. Infraclavicular block with lateral approach and nerve stimulation: extent of anesthesia and adverse effects. *Reg Anesth Pain Med.* 2002;27:590–594.
 378. Groban L, Deal DD, Vernon JC, James RL, Butterworth J. Ventricular arrhythmias with or without programmed electrical stimulation after incremental overdosage with lidocaine, bupivacaine, levobupivacaine, and ropivacaine. *Anesth Analg.* 2000;91:1103–1111.
 379. Groban L, Deal DD, Vernon JC, James RL, Butterworth J. Cardiac resuscitation after incremental overdosage with lidocaine, bupivacaine, levobupivacaine, and ropivacaine in anesthetized dogs. *Anesth Analg.* 2001;92:37–43.
 380. Litz RJ, Popp M, Stehr SN, Koch T. Successful resuscitation of a patient with ropivacaine-induced asystole after axillary plexus block using lipid infusion. *Anaesthesia.* 2006;61:800–801.
 381. Reinikainen M, Hedman A, Pelkonen O, Ruokonen E. Cardiac arrest after interscalene brachial plexus block with ropivacaine and lidocaine. *Acta Anaesthesiol Scand.* 2003;47:904–906.
 382. Borgeat A, Blumenthal S. Unintended destinations of local anesthetics. In: Neal JM, Rathmell JP, eds. *Complications in Regional Anesthesia and Pain Medicine.* Philadelphia: Saunders Elsevier; 2007:157–163.
 383. Lombard TP, Couper JL. Bilateral spread of analgesia following interscalene brachial plexus block. *Anesthesiology.* 1983;58:472–473.
 384. Sardesai AM, Patel R, Denny NM, Menon DK, Dixon K, Herrick MJ, et al. Interscalene brachial plexus block: can the risk of entering the spinal cord be reduced? A study of needle angles in volunteers undergoing magnetic resonance imaging. *Anesthesiology.* 2006;105:9–13.
 385. Alemanno F, Capozzoli G, Egarter-Vigl E, Gottin L, Alberto B. The middle interscalene block: cadaver study and clinical assessment. *Reg Anesth Pain Med.* 2006;31:563–568.
 386. Seltzer JL. Hoarseness and Horner's syndrome after interscalene brachial plexus block. *Anesth Analg.* 1977;56:585–586.
 387. Ekatodramis G, Macaire P, Borgeat A. Prolonged Horner syndrome due to neck hematoma after continuous interscalene block. *Anesthesiology.* 2001;95:801–803.
 388. Salengros JC, Jacquot C, Hesbois A, Vandesteene A, Engleman E, Pandin P. Delayed Horner's syndrome during a continuous infraclavicular brachial plexus block. *J Clin Anesth.* 2007;19:57–59.
 389. Neuberger M, Breitbarth J, Reisig F, Lang D, Buttner J. Complications and adverse events in continuous peripheral regional anesthesia. Results of investigations on 3,491 catheters. *Anaesthesist.* 2006;55:33–40.
 390. Hebl JR, Neal JM. Infectious complications: a new practice advisory [editorial]. *Reg Anesth Pain Med.* 2006;31:289–290.
 391. Hebl J. Importance and implications of aseptic techniques during regional anesthesia. *Reg Anesth Pain Med.* 2006;31:311–323.
 392. Wedel DJ. Regional anesthesia in the febrile or infected patient. *Reg Anesth Pain Med.* 2006;31:324–333.
 393. Horlocker T. Regional anesthesia and the immunocompromised patient. *Reg Anesth Pain Med.* 2006;31:334–345.
 394. D'Alessio JG, Weller RS, Rosenblum M. Activation of the

- Bezold-Jarisch reflex in the sitting position for shoulder arthroscopy using interscalene block. *Anesth Analg*. 1995;80:1158–1162.
395. Kahn RL, Hargett MJ. Beta-adrenergic blockers and vasovagal episodes during shoulder surgery in the sitting position under interscalene block. *Anesth Analg*. 1999;88:378–381.
 396. Liguori GA, Kahn RL, Gordon J, Gordon MA, Urban MK. The use of metoprolol and glycopyrrolate to prevent hypotension/bradycardic events during shoulder arthroscopy in the sitting position under interscalene block. *Anesth Analg*. 1998;87:1320–1325.
 397. Horlocker TT, Wedel DJ, Benzon H, Brown DL, Enneking FK, Heit JA, et al. Regional anesthesia in the anticoagulated patient: defining the risks (The Second ASRA Consensus Conference on Neuraxial Anesthesia and Anticoagulation). *Reg Anesth Pain Med*. 2003;28:172–197.
 398. Bhat R. Transient vascular insufficiency after axillary brachial plexus block in a child. *Anesth Analg*. 2004;98:1284–1285.
 399. Johns R, Di Fazio CA, Longnecker DE. Lidocaine constricts or dilates rat arterioles in a dose-dependent manner. *Anesthesiology*. 1985;62:141–144.
 400. Merrill DG, Brodsky JB, Hentz RV. Vascular insufficiency following axillary block of the brachial plexus. *Anesth Analg*. 1981;60:162–164.
 401. Ben-David B, Stahl S. Axillary block complicated by hematoma and radial nerve injury. *Reg Anesth Pain Med*. 1999;24:264–266.
 402. Liu HT, Yu YS, Liu CK, Sung CS, Chiou HF, Tsou MY, et al. Delayed recovery of radial nerve function after axillary block in a patient receiving ipsilateral ulnar nerve transposition surgery. *Acta Anaesthesiol Taiwan*. 2005;43:49–53.
 403. Zipkin M, Backus WW, Scott B, Poppers PJ. False aneurysm of the axillary artery following brachial plexus block. *J Clin Anesth*. 1991;3:143–145.
 404. Flowers GA, Meyers JF. Pseudoaneurysm after interscalene block for a rotator cuff repair. *Arthroscopy*. 2004;20:67–69.
 405. Ott B, Neuberger L, Frey HP. Obliteration of the axillary artery after axillary block. *Anaesthesia*. 1989;44:773–774.
 406. Hogan Q, Dotson R, Erickson S, Kettler R, Hogan K. Local anesthetic myotoxicity: a case and review. *Anesthesiology*. 1994;80:942–947.
 407. Zink W, Bohl JRE, Hacke N, Sinner B, Martin E, Graf BM. The long term myotoxic effects of bupivacaine and ropivacaine after continuous peripheral nerve blocks. *Anesth Analg*. 2005;101:548–554.
 408. Zink W, Seif C, Bohl JRE, Hacke N, Braun PM, Sinner B, et al. The acute myotoxic effects of bupivacaine and ropivacaine after continuous peripheral nerve blockades. *Anesth Analg*. 2003;97:1173–1179.
 409. Burgher AH, Hebl JR. Minimally invasive retrieval of knotted nonstimulating peripheral nerve catheters. *Reg Anesth Pain Med*. 2007;32:162–166.
 410. Chin KJ, Chee V. Perforation of a Pajunk stimulating catheter after traction-induced damage. *Reg Anesth Pain Med*. 2006;31:389–390.
 411. Tajima T. Considerations on the use of the tourniquet in surgery of the hand. *J Hand Surg* 1983;8:799–802.
 412. Klenerman L, Biswas M, Hulands GH, Rhodes AM. Systemic and local effects of the application of a tourniquet. *J Bone Joint Surg*. 1980;B62:385–388.
 413. Chabal C, Russell LC, Lee R. Tourniquet-induced limb ischemia: a neurophysiologic animal model. *Anesthesiology*. 1990;72:1038–1044.
 414. Benzon HT, Tolekis JR, Meagher LL, Shapiro BA, Ts'ao CH, Avram MJ. Changes in venous blood lactate, venous blood gases, and somatosensory evoked potentials after tourniquet application. *Anesthesiology*. 1988;69:677–682.
 415. Welti MK, Cassidy JD. Informed consent and documentation. In: Neal JM, Rathmell JP, eds. *Complications in Regional Anesthesia and Pain Medicine*. Philadelphia: Saunders Elsevier; 2007:361–370.
 416. Gerancher JC. Documentation of regional anesthesia procedures. In: Hadzic A, ed. *Textbook of Regional Anesthesia and Acute Pain Management*. New York: McGraw Hill Medical; 2007.
 417. Domino KB. Informed consent for regional anesthesia: what is necessary? [editorial]. *Reg Anesth Pain Med*. 2007;32:1–2.
 418. Gerancher JC, Viscusi ER, Liguori GA, McCartney CJ, Williams BA, Ilfeld BM, et al. Development of a standardized peripheral nerve block procedure note form. *Reg Anesth Pain Med*. 2005;30:67–71.
 419. Rupp SM. Manufacturing principles and human processes: can we create a safer system? [editorial]. *Reg Anesth Pain Med*. 2005;30:1–3.
 420. Rupp SM. Unintentional wrong-sided peripheral nerve block [editorial]. *Reg Anesth Pain Med*. 2008;33:95–97.
 421. Edmunds CR, Liguori GA, Stanton MA. Two cases of a wrong-site peripheral nerve block and a process to prevent this complication. *Reg Anesth Pain Med*. 2005;30:99–103.
 422. Stanton MA, Tong-Ngork S, Liguori GA, Edmunds CR. A new approach to preanesthetic site verification after 2 cases of wrong site peripheral nerve blocks. *Reg Anesth Pain Med*. 2008;33:174–177.
 423. Ilfeld BM, Enneking FK. Continuous peripheral nerve blocks at home: a review. *Anesth Analg*. 2005;100:1822–1833.
 424. Ilfeld BM, Esener DE, Morey TE, Enneking FK. Ambulatory perineural infusion: the patients' perspective. *Reg Anesth Pain Med*. 2003;28:418–423.
 425. Ludot H, Berger J, Pichenot V, Belouadah M, Madi K, Malvinovsky JM. Continuous peripheral nerve block for postoperative pain control at home: a prospective feasibility study in children. *Reg Anesth Pain Med*. 2008;33:52–56.
 426. Neal JM, Chan V. Ultrasound and regional anesthesia: a new section in Regional Anesthesia and Pain Medicine. *Reg Anesth Pain Med*. 2007;32:373–374.
 427. Urmey WF, Grossi P. Use of sequential electrical nerve stimuli (SENS) for location of the sciatic nerve and lumbar plexus. *Reg Anesth Pain Med*. 2006;31:463–469.
 428. Weinberg GL, Ripper R, Murphy P, Edelman L, Hoffman W, Strichartz G, et al. Lipid infusion accelerates removal of bupivacaine and recovery from bupivacaine toxicity in the isolated rat heart. *Reg Anesth Pain Med*. 2006;31:296–303.
 429. Naik VN, Perlas A, Chandra DB, Chung DY, Chan VWS. An assessment tool for brachial plexus regional anesthesia performance: establishing construct validity and reliability. *Reg Anesth Pain Med*. 2007;32:41–45.
 430. Pollard BA. New model for learning ultrasound-guided needle to target localization. *Reg Anesth Pain Med*. 2008;33:360–362.
 431. Hargett MJ, Beckman JD, Liguori GA, Neal JM. Guidelines for regional anesthesia fellowship training. *Reg Anesth Pain Med*. 2005;30:218–225.
 432. Sites BD, Chan VW, Neal JM, Weller R, Grau T, Koscielniak-Nielsen Z, et al. The American Society of Regional Anesthesia and Pain Medicine (ASRA) and the European Society of Regional Anaesthesia and Pain Therapy (ESRA) Joint Committee recommendations for education and training in ultrasound guided regional anesthesia. *Reg Anesth Pain Med*. 2009;34:40–46.
 433. Liu SS, Negeow JE, Yadeau JT. Ultrasound-guided regional anesthesia and analgesia: a qualitative systematic review. *Reg Anesth Pain Med*. 2009;34:47–59.
 434. Schwinn DA, Balser JR. Anesthesiology physician scientists in academic medicine: a wake-up call. *Anesthesiology*. 2006;104:170–178.
 435. Ilfeld BM, Yaksh TL, Neal JM. Mandating two-year regional anesthesia fellowships: fanning the academic flame or extinguishing it? *Reg Anesth Pain Med*. 2007;32:275–279.